


Supplement to

Endovascular TODAY

January 2007

The Next Generation of Endovenous Ablation

Segmental ablation of the GSV




Experts Discuss
New Devices
and Techniques


Device for perforator treatment

The Next Generation of Endovenous Ablation

Segmental ablation of the GSV
VNUS® ClosureFAST™ Catheter



Device for perforator treatment
VNUS® ClosureRFS™ Stylet



A Pioneering Technology Reinvented

BY LIAN X. CUNNINGHAM, MD, PhD

It is estimated that 25 million people suffer from symptoms associated with superficial venous insufficiency and varicose veins. For many years, the progressive severity of these disorders was largely underappreciated, with many patients enduring untreated symptoms, leading to decreased quality of life. Recent technology advancements in minimally invasive techniques have led to a renaissance in venous disease management, and an increasing number of these patients are now seeking treatment for their venous disorders.

During the late 1990s, endovenous radiofrequency ablation (RFA) emerged as the first widely adopted minimally invasive therapy for managing superficial truncal venous reflux. RFA was recognized not only for its efficacy, but also for the notably favorable patient recovery associated with the procedure, including reduced post-operative pain and faster return to normal activities.

In efforts to better meet the growing clinical need for safe and effective therapy as well as a faster and easier procedure, pioneering physicians have worked with VNUS Medical Technologies (San Jose, CA) to optimize

the devices available to today's vascular interventionists. The most recent technological advance in the field of endovenous ablation is the VNUS® ClosureFAST™ Radiofrequency Catheter, which was developed to improve the procedure speed and ease-of-use while maintaining the treatment outcomes and preferable patient recovery profile associated with previous RFA devices.

In this supplement to *Endovascular Today*, renowned experts in the field of chronic venous disease management have contributed in-depth articles on the overview of chronic venous disease, including its causes and the history of its treatment; detailed descriptions of today's minimally invasive technologies, with comparative analyses of current platforms; overviews of techniques for various types and anatomical locations of venous disease; and the essential elements for creating a successful vein care practice. We are very grateful to these authors for their contributions, and we hope you find this supplement to be comprehensive, informative, and beneficial to the care you provide to your venous disease patients.

CONTENTS

4 Overview of Chronic Venous Disease Management

A discussion of the history and improvements in diagnosing and treating venous insufficiency problems.

By Robert L. Kistner, MD

7 Clinical Use of the New VNUS ClosureFAST™ Radiofrequency Catheter

Segmental ablation technique facilitates quick and simple procedures.

By Alan B. Lumsden, MD,
and Eric K. Peden, MD

12 Comparison of Endovenous Ablation Techniques

New technologies and techniques allow more choice in endovenous ablation.

By Thomas M. Proebstle, MD

15 RF Ablation of Incompetent Perforators

Description of a technique using the VNUS ClosureRFS™ stylet.

By Eric K. Peden, MD, and Alan B. Lumsden, MD

19 RF Obliteration of Saphenous Reflux

Long-term outcomes of endovenous RF obliteration of saphenous reflux for treating superficial venous insufficiency.

By Robert F. Merchant, MD, FACS, and
Olivier Pichot, MD, for The Closure Study Group

22 Endoluminal Treatment of Lower-Limb Varicose Veins by Radiofrequency and Endovenous Laser

An overview comparing endoluminal and classic open treatment.

By Michel Perrin, MD

25 Building a Vein Practice

An overview of the important elements for creating your vein practice.

By Paul McNeill, MD

Overview of Chronic Venous Disease Management

A discussion of the history and improvements in diagnosing and treating venous insufficiency problems.

BY ROBERT L. KISTNER, MD

The management of chronic venous disease (CVD) has undergone enormous advances in the past few years. Beginning as a subjective, highly inexact process from antiquity until the 1970s, it has progressed to an objective, image-based diagnostic method complemented by evolving techniques to treat sites of reflux and obstruction. At present, the diagnostic procedures in CVD are in the process of standardization to achieve uniformity of results, and treatment procedures are being simplified by minimally invasive techniques to make the treatment better fit the disease.

CVD affects a very large percentage of the population. It is estimated that 20% of the adult population and 50% of women older than 50 years are affected; at least 6 million Americans have skin changes due to venous insufficiency.^{1,2} CVD is more frequent with advancing age and is more prevalent in women than in men younger than 50 years. Although CVD is often mild in presentation, it is a chronically progressive problem; in its more severe forms, it is equally frequent in men as in women. Its symptoms affect quality of life to a significant, if not a critical, degree and are generally underestimated. The estimated cost of care for venous ulcers is more than \$1 billion per year in the US.

A new awakening to the importance of CVD is occurring. For too long, it has been deemed a minor problem largely ignored by the medical profession. Because of this attitude, it has not been well-studied and has remained poorly understood. CVD is hardly mentioned in the medical school curriculum and is essentially ignored in medical and surgical training programs. As a result, the average physician has little knowledge of the disease progression, and the public is poorly served. This began to improve in the 1980s, when ultrasound diagnosis became available and accurate diagnoses of clinical disease became practical.

THE OVERALL DISEASE

To a large extent, CVD has been treated with elastic support stockings or neglect. The individual with vari-

cose veins who is symptomatic with mild-to-moderate aching, heaviness, leg fatigue, itching of the leg over varicose veins, with or without swelling in the ankle or lower leg, is most often managed by a general physician with advice to ignore the symptoms because varicose veins are not a serious problem, or perhaps a suggestion to try (nonprescription) support stockings and a reminder to elevate the legs. In its more advanced form of venous skin changes, including thickened, chronically inflamed tissues of the lower leg or even ulceration, the prescription too often is for a local ointment and a bandage of sorts, often without compression wrapping. Antibiotics are frequently prescribed in an inappropriate manner. Diuretics are probably used for swelling more often than effective support stockings.

This is all changing now. With the advent of accurate diagnosis by ultrasound scan and the recent availability of minimally invasive ablation of the saphenous veins and perforator veins, it has become practical and safe to diagnose the exact problem in the veins and offer definitive treatment for 80% to 90% of the problems by outpatient office-based procedures. The new standard of care for individuals with varicose veins, and those with thick leathery skin or ulceration of advanced venous disease, is to insist on an accurate, objective test to define the veins in the extremity and identify sites of abnormal venous segments. The abnormalities encountered are reflux and obstruction, which may occur at any site in a given extremity.

There are two main causes of CVD. The more frequent problem is primary (degenerative) disease of the vein wall with incompetence of the valves producing pure reflux, typified by varicose veins. Primary disease affects more than 80% of patients with CVD,³ and its manifestations usually begin in the superficial tissues with spider veins, reticular veins, and varicose veins. Over time, the reflux becomes progressive and affects the entire length of the saphenous system, the perforator veins, and ultimately the deep veins. When the local

reflux develops into axial reflux (from groin to calf), a continuous incompetent column exists from the heart to the ankle in the erect individual, and venous hypertension ensues. In its advanced stage, this hypertension results in thickening and ulceration in the skin of the lower leg that becomes disabling. This slow, decades-long process gives rise to true changes in the quality of life for a significant segment (5%) of the population.

The other large group of CVD cases is secondary postthrombotic disease, which has a very different life cycle. The cause is deep venous thrombosis that first appears in the deep veins rather than the superficial veins. It begins as a completely obstructive process and usually develops into a state of mixed reflux and obstruction over 6 to 24 months.⁴ This sets the stage for progressive deterioration that affects the skin of the lower leg in its mature state. The progression of postthrombotic disease to severe venous insufficiency is quicker than that of primary disease. Deep venous thrombosis has a marked tendency to recur and recurrence results in progression of the CVD state. When postthrombotic disease occurs in a patient with pre-existing primary reflux in the saphenous vein, the result is a markedly disadvantaged venous system with axial reflux of the superficial veins and axial obstruction/reflux in the deep veins, with the potential for rapid progression of the CVD state.

DIAGNOSIS

Duplex scanning has made the diagnosis of CVD an objective, image-based process. Ultrasound is almost the ideal test because it is painless, safe, affordable, repeatable, and widely practiced. However, the details of performing the test to detect reflux are more complicated than duplex scanning to detect venous thrombosis because reflux detection requires an analysis of valve function and segmental competence throughout the extremity from the groin to the calf, including perforator veins. The details of a complete CVD duplex scan of the lower extremity include the diagnosis of etiology, anatomic distribution of abnormalities in the superficial, perforator, and deep veins, and the segmental distribution of reflux and obstruction throughout the lower extremity. These elements are needed to complete the CEAP classification. The recently approved and revised CEAP classification⁵ is another innovation in the last decade that sets the basis for improved analysis and understanding of CVD entities. It permits accurate communication between institutions about the disease details and provides a universal method of reporting chronic venous disease.

Other tests include noninvasive plethysmography,

which provides quantitative information about degrees of obstruction and reflux. This information is most useful in advanced cases of CVD; in the future, it is possible that quantitative analysis of reflux will prove to have prognostic value in determining treatment alternatives.

Invasive tests of the veins include venous pressure, venography, and developing use of magnetic resonance venography and CT imaging. These tests are necessary in detailed analysis of advanced CVD states prior to deep vein surgery or interventions but are seldom needed in the 90% of venous insufficiency cases affecting the superficial and perforator veins with reflux disease.

TREATMENT

The long-established and still-cogent basis of treatment is external support using elastic stockings or inelastic compression in clinical management of all stages of CVD.⁶ Although there are many concepts about the mechanism through which compression results in clinical improvement, none are scientifically established. The fact is it reduces swelling, which is a basic necessity to control symptoms and promote wound healing in the distal tissues.

Definitive endovascular or surgical treatment for superficial, perforator, and deep reflux is available for all presentations of primary disease. Their use is based upon accurate duplex scan information of competence and obstruction throughout the segments of the venous tree. In the past decade, the development of minimally invasive correction of primary venous reflux in the saphenous and perforator veins by endovascular techniques has provided a patient-friendly means to treat the mass of primary reflux as an office-based procedure. The simplicity of the radiofrequency^{7,8} and laser⁹ techniques, and the developing interest in extending the safe use of injection sclerotherapy,¹⁰ is clearly important to improve quality of life for those with axial reflux and those with focal symptoms due to perforator incompetence. This has awakened huge interest in corrective management of these problems and replaces the need for unending use of external support for patients who can be converted to a normal or clinically compensated venous status.

The role of perforator reflux in venous return remains a poorly understood subject, but its elimination has proven beneficial effects in alleviating severe problems of leg pain, skin thickening, and ulceration.^{11,12} Until a few years ago, the diagnosis and treatment of perforator disease entailed invasive venography and open surgery. The definitive use of ultrasound to identify large perforator veins, the development of minimally invasive treatment first by sclerotherapy and later by SEPS (a less-invasive

surgical approach to interrupt the perforator veins below their fascial level), and the present employment of ultrasound-guided sclerotherapy and thermal elimination of incompetent perforator veins have converted control of perforator reflux to a simple outpatient procedure.

The combined eradication of superficial and perforator reflux now available in an ambulatory setting, with nearly zero downtime for the patient, is a tremendous advance in managing the mass of patients whose lives are affected by CVD. Further advances are in process, including better definition of diagnostic accuracy and simpler techniques of definitive treatment. The worldwide acceptance of the CEAP classification provides a means for interinstitutional communication and for development of scientific analysis of disease patterns and responses to treatment.

Although attention to the superficial and perforator veins provides for the majority of patients with primary disease, there remains the 10% to 15%³ of patients whose reflux or obstruction is located in the deep veins. Within this subset of patients are those who populate the wound care clinics, require a large amount of medical care, and generate much of the cost for society (approximately \$10,000/y per ulcer).² They are prone to recurrent and progressive ulceration in which the end result becomes disabling pain or swelling, and skin deterioration to the point of severe disability. Definitive treatment is available in a significant segment (>50% by personal experience) of these patients through advanced diagnostic workup and specific deep venous repair. These repairs are able to convert the venous disabled to near or full function for 4 years and beyond in a predictable percentage of cases.

Both open and endovascular surgical techniques are successfully practiced in venous treatment centers. Ascending and descending venography, complemented by selective use of venous pressure and plethysmography are needed for definitive diagnosis sufficient to guide surgery for these cases. Successful treatment by primary venous valve repair has been reported in several corroborative series¹³⁻¹⁵ for selected cases in both primary and postthrombotic disease. Deep surgical repair for selective cases of advanced postthrombotic states utilizing techniques of valve substitution, venous bypass, and endophlebectomy¹³⁻¹⁶ are available. A recent report described the creation of a successful autogenous neo-valve in postthrombotic disease.¹⁷ Iliac vein stenting for occlusive primary and secondary problems is reported to be highly successful at 4-year follow-up.¹⁸ The development of a successful valve implant continues to attract professional and industrial attention.

These procedures, pioneered in specific centers with an interest in finding effective ways to deal with complicated venous disease, are not widely available. They demand and deserve close scrutiny while we await the emergence of a safe, long-functioning venous valve replacement and the ability to remove obstructive material from long segments of badly diseased postthrombotic veins by simpler, less-invasive techniques.

SUMMARY

Tremendous advances of the past three decades have resulted in simple definitive diagnosis and treatment alternatives for the large mass of venous insufficiency problems. This gives hope for better control of the natural history of progression of CVD in primary disease and limitation of postthrombotic disease by earlier detection and better prevention in the immediate future. ■

Robert L. Kistner, MD, is Clinical Professor of Surgery, University of Hawaii, Kistner Vein Clinic, Honolulu, Hawaii. He has disclosed that he is a paid consultant to and owner or shareholder in VNUS. Dr. Kistner may be reached at (808) 532-8346; rlk@kistnerveinclinic.com.

1. Kurz X, Kahn SR, Abenheim L, et al. Chronic venous disorders of the leg: epidemiology, outcomes, diagnosis and management. Summary of an evidence-based report of the VEINES task force. *Venous Insufficiency Epidemiologic and Economic Studies*. *Int Angiol*. 1999;18:83-102.
2. Meissner MH, Eklof B, Gioviczi P, et al. Mapping the future of venous disease: an international summit. *J Vasc Surg*. 2007. In press.
3. Kistner RL, Eklof B, Masuda EM. Diagnosis of chronic venous disease of the lower extremities: the "CEAP" classification. *Mayo Clinic Proceed*. 1996;71:338-345.
4. Meissner M, Caps MT, Zierler B, et al. Determinants of chronic venous disease after acute deep venous thrombosis. *J Vasc Surg*. 1998;28:826-833.
5. Eklof B, Rutherford RB, Bergan JJ, et al. Revision of CEAP classification for chronic venous disorders: consensus statement. *J Vasc Surg*. 2004;40:1248-1252.
6. Motykie GD, Caprini JA, Arcelus JL, et al. Evaluation of therapeutic compression stockings in the treatment of chronic venous insufficiency. *Dermatol Surg*. 1999;25:116.
7. Merchant RF, Pichot O. Long-term outcomes of endovenous radiofrequency obliteration of saphenous reflux as a treatment for superficial venous insufficiency. *J Vasc Surg*. 2005;42:502-509.
8. Lurie F, Creton D, Eklof B, et al. Prospective randomized study of endovenous radiofrequency obliteration (closure) versus ligation and vein stripping (EVOLVEs): two-year follow-up. *Eur J Vasc Endovasc Surg*. 2005;29:67-73.
9. Pannier F, Rabe E. Endovenous laser therapy and radiofrequency ablation of saphenous varicose veins. *J Cardiovasc Surg*. 2006;47:3-8.
10. Cabrera J, Redondo P, Becerra A, et al. Ultrasound-guided injection of polidocanol microfoam in the management of venous leg ulcers. *Arch Dermatol*. 2004;140:667-673.
11. Gioviczi P, Bergan JJ, Rhodes JM, et al. Mid-term results of endoscopic perforator vein interruption for chronic venous insufficiency: lessons learned from the North American sub-fascial endoscopic perforator surgery registry. *The North American Study Group*. *J Vasc Surg*. 1999;29:489-502.
12. EM, Kessler DM, Lurie F, et al. The effect of ultrasound-guided sclerotherapy of incompetent perforator veins on venous clinical severity and disability scores. *J Vasc Surg*. 2006;43:551-557.
13. Masuda EM, Kistner RL. Long-term results of venous valve reconstruction: a four- to twenty-one-year follow-up. *J Vasc Surg*. 1994;19:391-403.
14. Raju S, Fredericks RK, Neglen PN, et al. Durability of venous valve reconstruction techniques for "primary" and postthrombotic reflux. *J Vasc Surg*. 1996;23:357-366; discussion 366-367.
15. Perrin M. Reconstructive surgery for deep venous reflux: a report on 144 cases. *Cardiovasc Surg*. 2000;8:246-255.
16. Puggioni A, Kistner RL, Eklof B, et al. Surgical disobliteration of postthrombotic deep veins—endophlebectomy—is feasible. *J Vasc Surg*. 2004;39:1048-1052.
17. Maletti O, Lugli M. Neovalve construction in postthrombotic syndrome. *J Vasc Surg*. 2006;43:794-799.
18. Neglen P, Hollis KC, Raju S. Combined saphenous ablation and iliac stent placement for complex severe chronic venous disease. *J Vasc Surg*. 2006;44:828-833.

Clinical Use of the New VNUS ClosureFAST™ Radiofrequency Catheter

Segmental ablation technique facilitates quick and simple procedures.

BY ALAN B. LUMSDEN, MD, AND ERIC K. PEDEN, MD

Although vein stripping, with some technical modifications, has been the standard of care for patients with superficial venous reflux and varicose veins for nearly a century, it is associated with significant postoperative morbidities. In addition, the 60% long-term recurrence rate has been disappointing.¹ As a result, many patients are managed conservatively and have suffered from compromised quality of life. In recent years, the introduction of new endovenous ablation technologies, namely the VNUS Closure® endovenous radiofrequency ablation (RFA) procedure (VNUS Medical Technologies, San Jose, CA) and endovenous laser treatments have stimulated much interest in venous disease management and has rejuvenated the field. Due to the minimally invasive nature of endovenous techniques, they have been widely adopted by practitioners and accepted by patients.



Figure 1. The ClosureFAST catheter and the RFGPlus™ generator.

The advantages of RFA over traditional vein stripping surgery are demonstrated in four randomized comparative trials.²⁻⁶ The most significant differences seen between RFA and vein stripping surgery are patient recovery, postoperative morbidities, and patient quality of life. The mean time to return to normal activity was 1.15 days versus 3.89 days ($P=.02$), and the percentage of patients returning to routine activities within 1 day was 80.5% versus 46.9% ($P<.01$) for the RFA and vein stripping surgery groups, respectively.² Use of RFA resulted in significantly less postoperative pain, either measured with visual analog scale or quality-of-life instruments, reduced need for analgesics, and fewer complications and adverse events in these studies.²⁻⁶ Patients treated with RFA experienced superior quality of life in both the short term and out to 2 years after treatment compared to those treated with vein stripping surgery.²⁻⁵ When comparing the two procedures on 16 patients with bilateral recurrent disease, RFA was faster, resulted in less postoperative pain and bruising, and had higher patient preference than vein stripping surgery.

The only randomized trial comparing endovenous laser (EVL) to vein stripping showed that patients experienced the same level of postoperative pain between the two groups, but EVL patients had less bruising and swelling than did patients who underwent vein stripping surgery.⁷

General procedure techniques are very similar between RFA and EVL. Both procedures involve ultrasound imaging guidance, vein access and catheter navigation, tumescent fluid infiltration, and continuous pullback of the catheter or laser fiber to deliver energy along the vein. However, the mechanism of action is different between the two technologies. RFA has a temperature-controlled feedback loop that monitors the vein wall contact with the catheter and controls energy

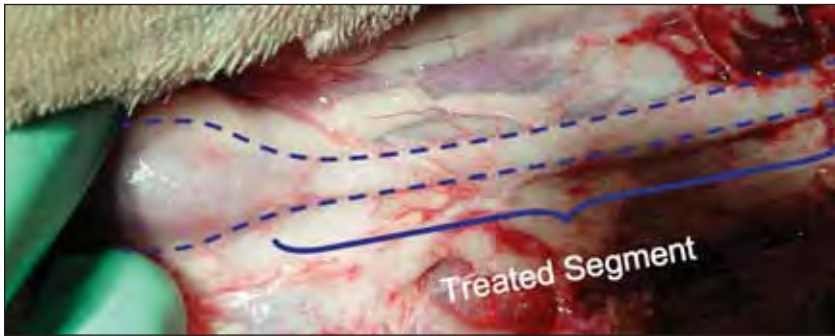


Figure 2. Significant shrinkage of the caprine jugular vein demonstrated by surgical exploration after ClosureFAST RFA.

delivery. The contact between the catheter electrodes and the vein wall is emphasized. The RF energy is delivered into the vein wall, causing immediate vein shrinkage and occlusion through collagen contraction and endothelium denudation, followed by inflammatory response and eventually fibrosis of the treated vein.⁸ In the case of EVL, because hemoglobin acts as a chromophore, local presence of blood is required to conduct laser energy. The energy delivered into the blood creates steam bubbles that injure the endothelium, causing thrombotic occlusion of the vein.⁹ It is generally believed that the two procedures result in similar treatment efficacy, but patients experience more pain and bruising after EVL due to vein wall perforation by the laser, resulting in thrombophlebitis. Two main disadvantages of RFA have been its slow pullback speed relative to EVL, and the annoyance associated with coagulum buildup on the electrodes, which occurs occasionally. This necessitates catheter removal, cleaning, and reinsertion.

THE CLOSUREFAST CATHETER

The ClosureFAST catheter is the next generation of Closure catheter that was developed to improve the procedure speed and the ease-of-use compared to the current Closure catheter. Shown in Figure 1, the catheter consists of a flexible catheter shaft and a 7-cm-long distal heating element. The heating element has a fixed diameter and is covered with a lubricious jacket to prevent sticking after heating. Good contact between the catheter and the vein wall is established by tumescent infiltra-

tion, Trendelenburg's position, and external compression, and is monitored by the thermocouple on the catheter and the computer software in the RF generator. The temperature of the heating element is monitored and controlled by a temperature sensor that regulates the amount of energy delivered during the treatment. Unlike current Closure and EVL devices, which involve continuous pull-back of the catheter or laser fiber during energy delivery, the

ClosureFAST catheter uses a "segmental heating" approach. Once the catheter is positioned and the vein is appropriately compressed, the heating element is activated with RF energy for the duration of the 20-second heating cycle. When the cycle is complete, energy delivery is automatically terminated by the generator, and the catheter is repositioned to the next treatment zone, as indicated by the shaft markers on the catheter. The catheter shaft is marked at increments of 6.5 cm, allowing for a 0.5-cm overlap between each treated segment to ensure complete treatment along the length. The ClosureFAST catheter is 7 F and is .025-inch-guidewire compatible.

A series of experiments was conducted to optimize the treatment parameters using caprine jugular and saphenous veins, which represent vessel diameters ranging from 2 mm to 15 mm. More than 100 vessels were treated at various combinations of temperature (95°C to 120°C) and time (10, 15, 20, or 30 seconds). Treatments at set temperature of 120°C and treatment time of 20 seconds showed excellent acute vein shrinkage

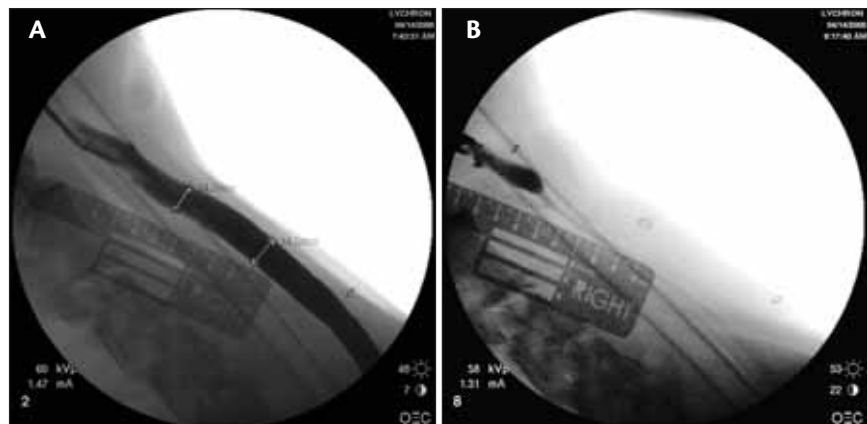


Figure 3. Venography of the caprine jugular vein before and after ClosureFAST ablation. Before treatment, the vein diameter is 14.2 mm to 14.5 mm (A). Immediately after treatment, there is complete elimination of blood flow (B).

(Figures 2 and 3) and complete elimination of blood flow in the caprine jugular vein, which represents a worse hemodynamic challenge than in saphenous veins due to the high-flow environment. The depth of thermal penetration evaluated by quantitative histological analysis was comparable to that of the current Closure procedure. At 5 days after the ablation, treated veins exhibited vein wall thickening and swelling, collagen denaturation, vessel lumen reduction, endothelial denudation, and vein wall inflammation. Fibrosis of treated veins was observed at 3 months after ablation (Figure 4).

CLINICAL EXPERIENCE

The initial clinical experience with the ClosureFAST catheter comes from Europe. To date, more than 200 limbs have been treated, with the longest follow-up being 6 months (T. M. Proebstle, personal communication, November 2006). All treated veins remained closed at the latest follow-up confirmed by ultrasound examinations. There has been no deep venous thrombosis, no

skin burns, or other serious adverse events. The average energy delivery time was 2.2 minutes, with an average treatment length of 37 cm, and the average time from catheter insertion to catheter removal was 16.6 minutes.

Our center was the first to use this new catheter in the US. The overall procedure steps are similar to current endovenous ablation procedures. There are a few important technical aspects with this procedure that are worth noting. Catheter identification by ultrasound has some subtle differences. Because there are no movable electrodes, the typical starburst appearance of ClosurePlus is absent. Sufficient perivenous tumescent infiltration and external compression along the entire length of the 7-cm heating element are essential to ensure good vein wall contact with the heating element and even heating along the length of the vein segment. Sufficient tumescence also provides perivenous tissue protection during heating. Extrinsic compression using the ultrasound transducer in the long axis, plus one or more fingers to provide compression along the entire length of the heating element, is recommended. The

Veinlite®

High Quality
Vein Transillumination
of the Skin

- Enhance small vein visualization
- Create a virtual light source under the skin
- Convenient and affordable

Nationwide Sales, Support and Service...
From the Endovenous Leader



Veinlite® I
High intensity
office instrument



Veinlite® LED
Lightweight,
portable device

Two models to choose from

TO ORDER, CALL 1-888-797-VEIN(8346)



www.vnus.com
Copyright © 2006 VNUS Medical Technologies, Inc. All Rights Reserved.

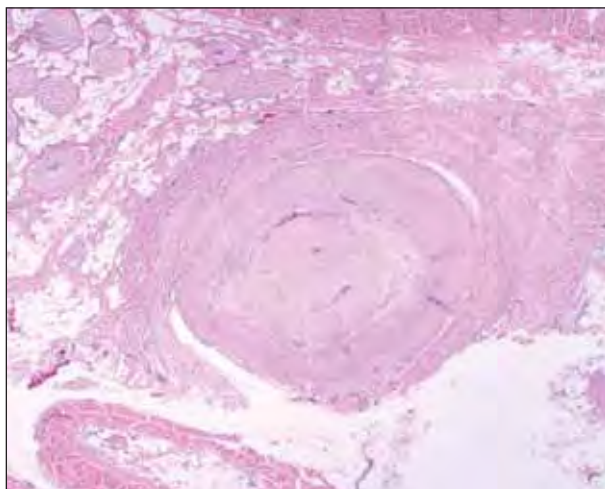


Figure 4. Histologic representation of a treated vein 3 months after ablation.

new catheter does not require a saline drip, which is different from previous RFA, and it appears to completely eliminate the high impedance issues caused by coagulum buildup with the previous catheter. During energy delivery, the ClosureFAST catheter remains stationary, and a 7-cm vein segment is heated at once. After completion of the 20-second heating cycle, the catheter is positioned to the next segment guided by the shaft markers, and treatment starts again. Accurate pullback is facilitated by positioning the sheath to align with one of the 6.5-cm markers on the catheter shaft. Two heating cycles are applied to the first segment near the saphenofemoral junction to ensure sufficient treatment of this important segment. The segmental ablation technique not only dramatically speeds up the procedure but, more importantly, it eliminates the impact of pullback speed variation and its resultant energy dose variation on procedure efficacy, which has been shown to be a risk factor for procedure failure in both RFA and EVL.⁹⁻¹¹

The procedure was well-tolerated by the patients. In our experience, under local anesthesia without sedation, there was no noticeable difference in patient reaction to this procedure compared to the current Closure procedure. Postprocedural patient recovery was remarkably benign. Seventy-nine percent of limbs experienced no pain and 87% experienced no tenderness after treatment (T. M. Proebstle, personal communication, November 2006). Our experience concurs with that reported in the European study. This is an important distinction between RFA and EVL. After EVL, 67% to 100% of patients reported to have some degree of pain, and more than 50% of patients required analgesics for pain management.^{9,12} A 10% to 33% thrombophlebitis

rate, and a pain score of 2.2-2.6 on a 1 to 5 scale after EVL were reported by Kabnick using 980-nm and 810-nm lasers.¹³ The pain, bruising, and thrombophlebitis are thought to be the result of vein wall perforation and the thrombotic mechanism associated with EVL.

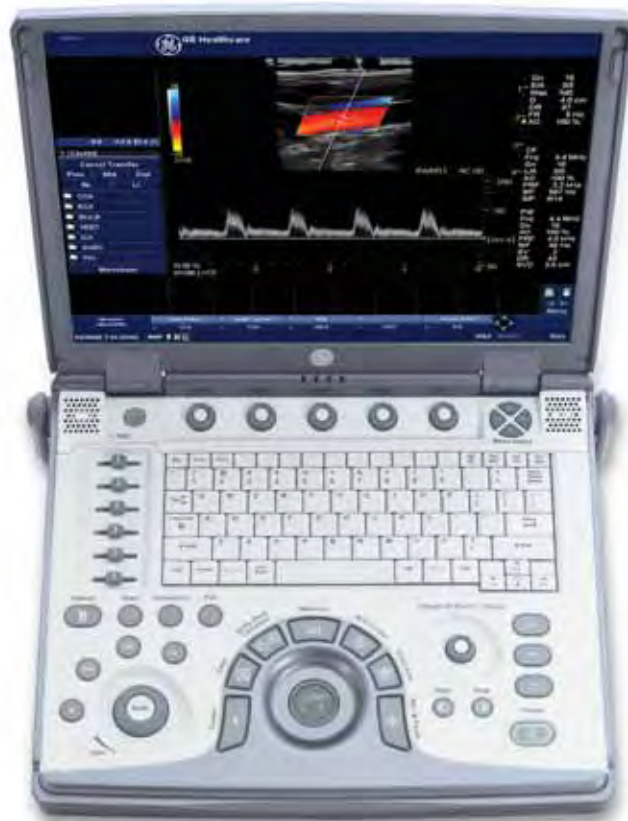CONCLUSION

The new ClosureFAST catheter exhibited the advantages of mild patient recovery with use of current RFA technique, coupled with the fast procedure speed of EVL. The novel concept of segmental ablation eliminates the pullback speed variability with the current RFA and EVL techniques, and further simplifies the procedure. With limited experience at our center, the ClosureFAST catheter has demonstrated excellent treatment outcomes. ■

Alan B. Lumsden, MD, is from the Department of Cardiovascular Surgery, Methodist DeBakey Heart Center, The Methodist Hospital, Houston, Texas. He has disclosed that he is a consultant to VNUS. Dr. Lumsden may be reached at (713) 798-8831; alumsden@bcm.tmc.edu.

Eric K. Peden, MD, is from the Department of Cardiovascular Surgery, Methodist DeBakey Heart Center, The Methodist Hospital, Houston, Texas. He has disclosed that he holds no financial interest in any product or manufacturer mentioned herein. Dr. Peden may be reached at (713) 798-2151; epeden@bcm.edu.

1. Fischer R, Chandler JG, De Maeseneer MG, et al. The unresolved problem of recurrent saphenofemoral reflux. *J Am Coll Surg.* 2002;195:80-94.
2. Lurie F, Creton D, Eklof B, et al. Prospective randomized study of endovenous radiofrequency obliteration (Closure) versus ligation and stripping in a selected patient population (EVOLVE study). *J Vasc Surg.* 2003;38:207-214.
3. Lurie F, Creton D, Eklof B, et al. Prospective randomised study of endovenous radiofrequency obliteration (Closure) versus ligation and vein stripping (EVOLVE): two-year follow-up. *Eur J Vasc Endovasc Surg.* 2005;29:67-73.
4. Rautio T, Ohinmaa A, Perälä J, et al. Endovenous obliteration versus conventional stripping operation in the treatment of primary varicose veins: a randomized controlled trial with comparison of costs. *J Vasc Surg.* 2002;35:958-965.
5. Stötter L, Schaaf I, Bockelbrink A. Comparative outcomes of radiofrequency endoluminal ablation, invagination stripping, and cryostripping in the treatment of great saphenous vein insufficiency. *Phlebology.* 2006;21:60-65.
6. Hinchliffe RJ, Ubhi J, Beech A, et al. A prospective randomised controlled trial of VNUS Closure versus surgery for the treatment of recurrent long saphenous varicose veins. *Eur J Vasc Endovasc Surg.* 2006;31:212-218.
7. de Medeiros CA, Luccas GC. Comparison of endovenous treatment with an 810 nm laser versus conventional stripping of the great saphenous vein in patients with primary varicose veins. *Dermatol Surg.* 2005;31:1685-1694.
8. Weiss RA. RF-mediated endovenous occlusion. In: Weiss RA, Feied CF, Weiss MA, eds. *Vein diagnosis and treatment: a comprehensive approach.* New York, NY: McGraw-Hill Medical Publishing; 2001:211-221.
9. Proebstle TM, Lehr HA, Kargl A, et al. Endovenous treatment of the greater saphenous vein with a 940-nm diode laser: thrombotic occlusion after endoluminal thermal damage by laser-generated steam bubbles. *J Vasc Surg.* 2002;35:729-736.
10. Merchant RF, Pichot O, for the Closure study group. Long-term outcomes of endovenous radiofrequency obliteration of saphenous reflux as a treatment for superficial venous insufficiency. *J Vasc Surg.* 2005;42:502-509.
11. Timperman PE, Sichlau M, Ryu RK. Greater energy delivery improves treatment success of endovenous laser treatment of incompetent saphenous veins. *J Vasc Interv Radiol.* 2004;15:1061-1063.
12. Proebstle TM, Krummenauer F, Gul D, et al. Nonocclusion and early reopening of the great saphenous vein after endovenous laser treatment is fluence dependent. *Dermatol Surg.* 2004;30:174-178.
13. Kabnick LS. Outcome of different endovenous laser wavelengths for great saphenous vein ablation. *J Vasc Surg.* 2006;43:88-93.



Caution: May cause disbelief.

Uncompromised image quality, from the office to the OR.

GE Healthcare's new LOGIQ *e* delivers best-in-class image quality and large-scale functionality in a compact product. This is achieved through advanced technology features like CrossXBeam™, a GE exclusive.

Imagine seeing the tiniest anatomy clearly. Making critical decisions quickly. And in turn, providing excellent patient care.

For more detail, visit our website at www.gehealthcare.com/ultrasound or call 888-526-5144.



imagination at work

Comparison of Endovenous Ablation Techniques

New technologies and techniques allow more choice in endovenous ablation.

BY THOMAS M. PROEBSTLE, MD

In general, endovenous ablation of varicose veins can be performed chemically by injection of sclerosants, or thermally by the use of catheter-based systems.

Sclerosants can be used as liquids or foam, and they can be administered by simple needle injection or by the use of more or less sophisticated ultrasound-controlled catheter techniques. Thermal ablation systems are more effective than sclerosants in achieving immediate and more durable vein occlusions when treating saphenous veins. They produce heat in the vein wall by resistive heating of water molecules by bipolar radiofrequency (RF) current (460 kHz), or by delivery of infrared laser energy through flexible lightguides to the vein lumen. The most recent technology entering clinical routine treatment delivers energy to the vein wall by RF heating of a 7-cm-long catheter tip segment to 120°C. All endovenous techniques for vein ablation rely on continuous ultrasound B-scan monitoring and can be performed under tumescent local anesthesia.

SCLEROSANTS

Endovascular abolition of varicose veins can be achieved by injection of chemically active substances, such as polidocanol or sodium tetradecyl sulfate, which are used as liquid or foam. They act as detergents to remove the endothelial layer and provide substantial damage to the media layer of the vein wall. Consequently, a clot has to occlude the vein before a subsequent inflammatory tissue response finally leads to a fibrotic cord several weeks or months later. Foam sclerotherapy is more effective in achieving such results than liquid sclerotherapy.^{1,2} However, safety issues of sclerotherapy need some special consideration. In addition to common side effects such as thrombophlebitis and hyperpigmentation of the skin,³ which happen less frequently with thermal techniques, sclerotherapy-specific side effects, such as visual disturbance and central nervous symptoms of short duration, occur infrequently. Even a stroke has been reported after the use of sclerosant foam.⁴ In patients with an open foramen ovale, these

“Thermal ablation systems are more effective than sclerosants in achieving immediate and more durable vein occlusions when treating saphenous veins.”

latter events may be linked to passing of bubbles through the carotids only a few seconds after injection of the sclerosant foam in the leg. Therefore, a limitation of the injection volume for foam seems to be reasonable; however, different groups around the world still suggest different maximum volumes.

With respect to efficacy, results are varying. Certainly, foam sclerotherapy allows the treatment of primary and particularly recurrent varicose veins in patients with advanced venous disease.^{5,6} However, in a recent publication, a single sclerotherapy session with 3% sodium tetradecyl sulphate Tessari foam produced adequate treatment results in only 58% of treated legs; a total of 87% of legs could be treated adequately with at least one more additional sclerotherapy session.⁷ Another study reported great saphenous vein occlusion in 56 of 70 cases (80%) after 3% sodium tetradecyl sulphate foam treatment⁸ when the great saphenous vein was cannulated. However, when using foam sclerotherapy instead of vein stripping to abolish great saphenous vein reflux as an adjunctive measure to high ligation, the clinical results were similar although foam treatment was cheaper, and foam patients returned to normal activities after 2 days instead of 8 days after stripping.⁹ Even if sclerotherapy alone is not as effective for ablation of saphenous veins as are thermal ablation techniques, it seems to be the endovenous ablation technique of choice for treating recurrent varicose veins after surgery, or in saphenous veins with incomplete recanalization after preceding phlebitis.

THERMAL ABLATION TECHNIQUES

Thermal techniques rely on the delivery of heat to the vein wall by use of high-frequency electrical current or laser energy through special RF catheters or laser light-guides. These catheters are usually placed by means of Seldinger's technique under ultrasound control. Most frequently, the delivery of energy is performed solely under tumescent local anesthesia.

“Most strikingly, return to normal physical activity and return to work were significantly shortened when using RF closure if compared to high ligation/stripping.”

RF Closure

RF closure was the first technique to reach the level of widespread clinical use for treating the great saphenous vein.¹⁰ A bipolar endovenous catheter system with a feedback mechanism uses a 460-kHz current to heat the vein wall to a target temperature with power typically in the range of 2 to 4 W. Polar molecules, such as water, transfer electrical energy to heat energy by current-induced molecular movement resulting in temperatures between 85°C and 90°C at the vein wall. To avoid drainage of heat energy by intravascular blood flow, the vein must be emptied as much as possible by means of placing the patient in Trendelenburg position and the use of external compression. These maneuvers result in full contact between the vein wall and the catheter tip electrodes. Together with a slow initial catheter pullback rate in the range of 1 cm/min, followed by 2 to 4 cm/min thereafter, the vein wall collagen undergoes a relevant shrinkage process that is more pronounced than observed with laser and is almost absent with sclerotherapy.

RF closure in the meantime has a solid literature basis, including randomized trials in comparison to ligation/stripping,¹¹ and long-term studies with up to 5-year follow-up are available.¹² Long-term rates of great saphenous vein occlusion at 5 years after treatment proved to be in the range of 85% to 90% and, unlike after surgical treatment of the saphenofemoral junction, no neovascularization could be observed. Most strikingly, return to normal physical activity and return to work were significantly shortened when using RF closure if compared to high ligation/stripping.¹¹

Laser Treatment

Endovenous laser treatment of the great saphenous

vein developed during the last years of the 20th century. However, it took until 2001 to bring it to the attention of the scientific community;¹³ the first systematic review on endovenous laser ablation did not appear until 2005.¹⁴ The most frequently used lasers are diode lasers, with wavelengths between 810 nm and 980 nm.^{13,15,16} However, 1,064-nm Nd:YAG solid state lasers¹⁷ can be used for endovenous laser treatment. The laser wavelengths are predominantly absorbed by hemoglobin,¹⁸ which is needed intravenously to a small extent to guarantee successful laser treatment. However, vein wall shrinkage after laser treatment is less pronounced if compared to RF ablation¹⁹ and vein wall perforations are unavoidable to a certain extent. These vein wall perforations are obviously linked to the escape of heat energy to the perivenous compartment and most likely account for a more pronounced side effect spectrum if compared to RF. Only recently, a 1,320-nm laser using water absorption for endovenous energy transfer was introduced, partially overcoming these problems.²⁰ In contrast to diode lasers, with 1,320-nm laser energy, the vein wall is gently cooked and shrunken. Perforations of the vein wall are much less frequent with the recommended setting of laser power. When comparing the side effect profile of diode lasers to 1,320-nm lasers, the side effects of a 1,320-nm laser occur less frequently and are observed for shorter durations. For side effects, the 1,320-nm laser behaves more like RF ablation than like a typical diode laser. However, RF ablation, in our experience, provides the lowest rate of side effects and the best level of patient outcomes and satisfaction.

Energy Dosing

Regardless of which technique is used for endovenous thermal ablation, substantial heat transfer to the vein wall is necessary for immediate and durable occlusion of the treated vein. Too high of a retraction speed of the catheter during RF ablation is known to be associated with a higher rate of treatment failures or recanalizations of the treated vein. The same is true for pulling back the laser fiber too quickly during treatment, which results in insufficient dosing of heat energy. It already has been linked to nonocclusion and to a substantial rate of early recanalizations of the treated vein.²¹ Other publications indicated that the administration of a linear endovenous energy density of 80 J/cm of vein length helps to reduce the frequency of recanalization events during short-term follow-up^{22,23} supporting the concept of dose response in endovenous laser treatment. Very recently, a vein diameter-dependent energy dosing schedule based on clinical follow-up data was proposed.²⁴

“The new ClosureFAST system is an important advancement that combines the speed of laser treatment with the favorable side effect profile of RF ablation.”

LATEST DEVELOPMENTS

Once recognizing the concept of energy dosing for successful endovenous vein ablation, the design of new catheter-type devices for administration of endovenous heat energy seemed logical. The latest example now entering the field is the ClosureFAST™ catheter (VNUS Medical Technologies, San Jose, CA). With use of the ClosureFAST catheter, a 7-cm element at the catheter tip is simply heated to 120°C for 20 seconds while the catheter position is stationary. It is no longer necessary to allow current to flow through patients' tissue nor deliver raw laser energy to the endovenous space. With this new device, a 40-cm-long vein segment can be treated stepwise in less than 3 minutes, which is equivalent to the speed of the fastest laser treatment protocols. Additionally, the rate of immediate vein occlusion at the saphenofemoral junction is 100%, a value that was not reached by many users of laser and RF previously. Furthermore, the low side effect profile with ClosureFAST is clearly the same as with the previous RF ablation. These data are unpublished but resemble the author's personal experience performing ClosureFAST on almost 100 legs from April 2006 to October 2006 (first scientific communication to be presented at AVF 2007, San Diego, CA).

CONCLUSION

Today, phlebologists have the choice of a variety of endovenous ablation techniques. Postinterventional impairment of a patient's quality of life after traditional high ligation and stripping surgery can be significantly reduced. Foam sclerotherapy, even if it is not as effective in ablation of saphenous veins as thermal techniques, seems to be the first choice for treating recurrent varicose veins. Thermal techniques themselves, appropriately delivered, can now guarantee immediate vein occlusion in almost 100% of cases. Particularly, the new ClosureFAST system is an important advancement that combines the speed of laser treatment with the favorable side effect profile of RF ablation. ■

Thomas M. Proebstle, MD, is from the Department of Dermatology, University of Heidelberg, Germany. He has disclosed that he is a paid consultant to and receives

research grant funding from VNUS. Dr. Proebstle may be reached at thomas.proebstle@med.uni-heidelberg.de.

- Hamel-Desnos C, Desnos P, Wollman JC, et al. Evaluation of the efficacy of polidocanol in the form of foam compared with liquid form in sclerotherapy of the greater saphenous vein: initial results. *Dermatol Surg.* 2003;29:1170-1175.
- Yamaki T, Nozaki M, Iwasaka S. Comparative study of duplex-guided foam sclerotherapy and duplex-guided liquid sclerotherapy for the treatment of superficial venous insufficiency. *Dermatol Surg.* 2004;30:718-722.
- Coleridge Smith P. Saphenous ablation: sclerosant or sclerofoam? *Semin Vasc Surg.* 2005;18:19-24.
- Forlè MV, Grouden M, Moore DJ, et al. Stroke after varicose vein foam injection sclerotherapy. *J Vasc Surg.* 2006;43:162-164.
- Rao J, Wildermore JK, Goldman MP. Double-blind prospective comparative trial between foamed and liquid polidocanol and sodium tetradecyl sulfate in the treatment of varicose and teleangiectatic leg veins. *Dermatol Surg.* 2005;31:631-635.
- Bergan JJ, Pascarella L. Severe chronic venous insufficiency: primary treatment with sclerofoam. *Semin Vasc Surg.* 2005;18:49-56.
- Kakkos SK, Bourountoglou DG, Azzam M, et al. Effectiveness and safety of ultrasound-guided foam sclerotherapy for recurrent varicose veins: immediate results. *J Endovasc Ther.* 2006;13:357-364.
- Darte SG, Baker SJ. Ultrasound-guided foam sclerotherapy for the treatment of varicose veins. *Br J Surg.* 2006;93:969-974.
- Bourountoglou DG, Azzam M, Kakkos SK, et al. Ultrasound-guided foam sclerotherapy combined with sapheno-femoral ligation compared to surgical treatment of varicose veins: early results of a randomized controlled trial. *Eur J Endovasc Surg.* 2006;31:93-100.
- Chandler JG, Pichot O, Sessa C, et al. Defining the role of extended saphenofemoral junction ligation prospective comparative study. *J Vasc Surg.* 2000;32:941-953.
- Lurie F, Creton D, Eklof B, et al. Prospective randomised trial of endovenous radiofrequency obliteration (closure) versus ligation and stripping (EVOLVEs): two year follow-up. *Eur J Vasc Endovasc Surg.* 2005;29:67-73.
- Merchant RF, Pichot O, Closure Study Group. Long-term outcomes of endovenous radiofrequency obliteration of saphenous reflux as a treatment for superficial venous insufficiency. *J Vasc Surg.* 2005;42:502-509.
- Navarro L, Min R, Boné C. Endovenous laser: a new minimally invasive method of treatment of varicose veins—preliminary observations using an 810 nm diode laser. *Dermatol Surg.* 2001;27:117-122.
- Mundy L, Merlin TL, Filtridge RA, et al. Systematic review of endovenous laser treatment for varicose veins. *Br J Surg.* 2005;92:1189-1194.
- Proebstle TM, Lehr HA, Kargl A, et al. Endovenous treatment of the greater saphenous vein with a 940 nm diode laser: thrombotic occlusion after endoluminal thermal damage by laser generated steam bubbles. *J Vasc Surg.* 2002;35:729-736.
- Gerard J-L, Desgranges P, Becquemin J-P, et al. Feasibility of ambulatory endovenous laser for the treatment of greater saphenous varicose veins: one-month outcome in a series of 20 outpatients. *J Mal Vasc.* 2002;27:222-225.
- Chang CJ, Chua JJ. Endovenous laser photocoagulation (EVLV) for varicose veins. *Lasers Surg Med.* 2002;31:257-262.
- Roggan A, Friebe M, Dorschel K. Optical properties of circulating human blood in the wavelength range 400 -2500 nm. *J Biomed Opt.* 1999;50:532-539.
- Weiss RA. Comparison of endovenous radiofrequency versus 810 nm diode laser occlusion of large veins in an animal model. *Dermatol Surg.* 2002;28:56-61.
- Goldman MP, Mauricio M, Rao J. Intravascular 1320 nm laser closure of the great saphenous vein: a 6 to 12 months follow-up study. *Dermatol Surg.* 2004;30:1380-1385.
- Proebstle TM, Gül D, Kargl A, et al. Non-occlusion and early reopening of the great saphenous vein after endovenous laser treatment is fluence dependent. *Dermatol Surg.* 2004;30:174-178.
- Timperman PE, Sichlau M, Ryu RK. Greater energy delivery improves treatment success of endovenous laser treatment of incompetent saphenous veins. *J Vasc Interv Radiol.* 2004;15:1061-1063.
- Timperman PE. Prospective evaluation of higher energy great saphenous vein endovenous treatment. *J Vasc Interv Radiol.* 2005;16:791-794.
- Proebstle TM, Moehler T, Herdemann S. Reduced recanalization rates of the great saphenous vein after endovenous laser treatment with increased energy dosing: definition of a threshold for the endovenous fluence equivalent. *J Vasc Surg.* 2006;44:834-839.

RF Ablation of Incompetent Perforators

Description of a technique using the VNUS ClosureRFS™ stylet.

BY ERIC K. PEDEN, MD, AND ALAN B. LUMSDEN, MD

Chronic venous insufficiency (CVI) occurs in a large portion of the population and is associated with significant morbidity, high health care costs, loss of productivity, and a reduced quality of life. There is substantial evidence for the role of incompetent perforator veins (IPVs) in the pathogenesis of advanced CVI. Classic studies by Linton¹ and Cockett² emphasized the contribution of IPVs to CVI. It has been reported that as many as 66% of limbs with skin changes have perforator reflux in conjunction with superficial or deep venous incompetence.³ In addition, 63% of recurrent varicose veins are associated with IPVs.⁴ Numerous investigators have reported on the benefit of interruption of IPVs.⁵⁻⁹

Traditional treatment options for IPVs include open surgery and subfascial endoscopic perforator surgery (SEPS). SEPS has been shown to accelerate ulcer healing with far fewer wound healing complications than the Linton procedure.^{5,10-12} Although SEPS has recently been the most common procedure to treat IPVs, its inability to access all IPVs, its significant long-term recurrence of IPVs and venous ulcers, and its limitation in repeat treatment¹³ leave room for better treatment options.

Ablation of the saphenous vein has largely replaced vein stripping, and the technique has been extended to treatment of IPVs. Whiteley reported the first results of using the VNUS Closure® catheter (VNUS Medical Technologies, San

Jose, CA) for ablation of perforator veins.¹⁴ The procedure was performed on 770 IPVs in a total of 506 limbs. At 1 year, 79% of IPVs were closed and had atrophied. By the second year, 76% remained closed and atrophied. This early success of radiofrequency ablation (RFA) treatment of IPVs led to the design of the radiofrequency stylet (RFS) device. The system received FDA clearance in January 2004. Since June 2004, there has been an ongoing multicenter study of perforator ablation using the VNUS RFS device.

CVI INVESTIGATION AND TREATMENT ALGORITHM

We generally reserve treatment of IPVs for patients with advanced CVI; and clinical, etiologic, anatomic, pathophysiologic (CEAP) classes 4 to 6, although it can be performed as part of the primary treatment for varicose veins and is useful in treating recurrent varicose veins. Our treatment algorithm and treatment options offered to the patients are based on the four functional segments of the venous system of the lower limb: pelvic outflow, deep veins, superficial veins, and perforator veins. We typically perform the treatments that are minimally invasive first: endovascular treatment of pelvic outflow obstructions, superficial ablation, and perforator ablation. Deep system reconstruction is reserved for patients in whom simpler treatments fail. The ability to ablate the perforating system percutaneously has changed our algorithm in that it used to be reserved in the form of SEPS for those patients who failed to respond to superficial ablation with or without pelvic outflow treatment.

Although the procedures can be staged, we routinely perform superficial ablation and perforator ablations at the same setting. The procedure can be performed in the operating room with general or regional anesthesia. Alternatively, the procedure is routinely performed in the office with local anesthetics, with or without oral anxiolytics.

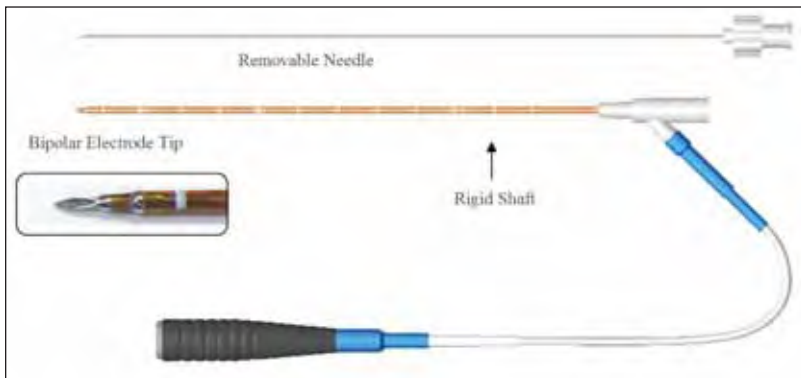


Figure 1. The ClosureRFS device.

IPV TREATMENT WITH RFA

The procedure of percutaneous RFA of perforating veins remains an evolving procedure, with several variations described. There are two RFS devices currently available, one flexible and one rigid. The overwhelming majority of procedures are performed with the rigid device, which has two electrodes on the shaft with a removable needle trocar (Figure 1).

The patient is positioned and prepared in the reverse Trendelenburg position. Ultrasound imaging is then performed medially from the submalleolar region up to the knee. IPV's are marked on the skin where they penetrate the fascia (Figure 2). Each IPV location is documented by its distance from the medial malleolus and tibia for localization during follow-up studies.

Accessing the IPV can be performed by one of three methods. The rigid trocar can be used to directly puncture the IPV after a small skin incision is created. It is of note that some resistance is encountered as the probe traverses the fascia. Another method is to use a 12-gauge IV catheter to access the vein and then to pass either the rigid or flexible device through the IV catheter after the needle trocar is removed. Finally, a needle can be used to access the IPV, and a .035-inch guidewire can be passed into the deep venous system. A dilator is then used to create a tract through the skin and fascia, and then the rigid device can be passed over the wire into the perforating vein.

It is preferable to access the vein such that a length of vein is cannulated, allowing a pullback treatment (Figure 3A). If that is not possible, it is preferred to do two focal treatments instead of a single focal treatment (Figure 3B). The IPV needs to be treated in a subfascial segment to have the best results because treatments above the fascia have been shown to have higher failure rates. The tip of the RFS device should be at least 5 mm from the deep system to reduce the chance of deep vein thrombosis, although treatment with as little as 3 mm has been performed safely. The depth of the RFS device from the skin has not been an issue and, in some areas, particularly the submalleolar area, it has frequently been less than 1 cm. Curiously, skin burn has been very rare in the early experience with this procedure despite infrequent use of tumescence and the close proximity to the skin, which is in contrast to the findings of RFA of the saphenous vein, where a depth less than a centimeter from the skin has an increased risk of skin burns.

The IPV is first visualized, and reflux is confirmed using duplex ultrasound (Figure 4A). The vein is best accessed using longitudinal viewing with the entire

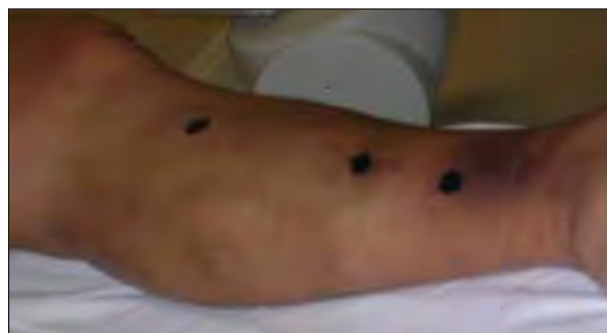

Figure 2. These marks indicate the location of perforators.

length of the needle visualized in relation to the IPV and the deep veins (Figure 4B). Upon accessing the vein, a flash of blood should be seen to confirm intravascular access. To achieve the best outcomes, it is extremely important to be intravascular with the device. Extravascular treatment seems to have few complications, but does result in decreased closure rate of the perforators.

If a pullback method is to be performed, the vein is treated for 4 minutes at 85°C, with firm compression of the vein using the ultrasound probe. Approximately 80 to 90 mm Hg of pressure is needed to reduce IPV diameter to allow vein wall contact during treatment. A second treatment is then performed approximately 1 cm from the first treatment for 2 minutes at 85°C. During these treatments, it is recommended to angulate the RFS device into the four quadrants for equal periods of time to ensure good wall contact. If pullback is not possible, two focal treatments at two separate areas for 4 minutes each are recommended. If the procedure is being performed in the clinic with local anesthetic, tumescent infiltration must be performed prior to activating the RFS, or the patient will feel a burning sensation. Visualization is very difficult after tumescence has been instilled, further emphasizing the importance of accurate intravascular catheter placement.

Impedance levels should be between 150 and 350 Ω , with power levels of < 3.5 W, which indicates good vein wall con-

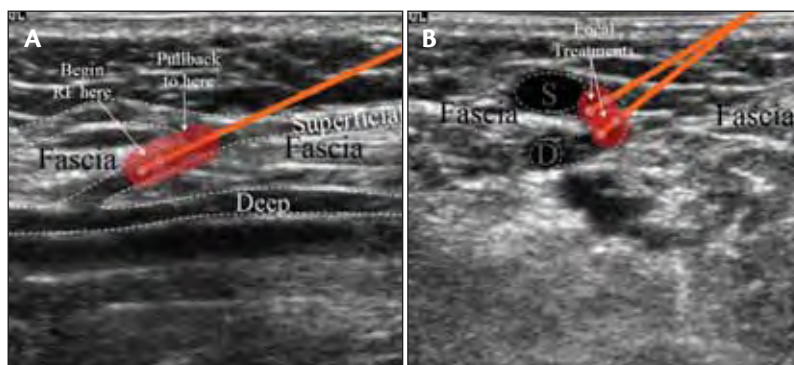


Figure 3. The pullback treatment method (A) and two focal treatments (B).

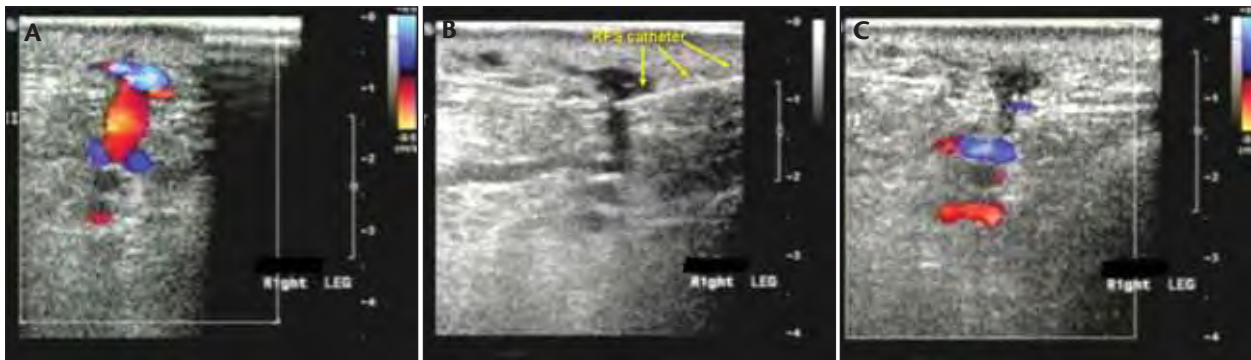


Figure 4. A perforator before (A), during (B), and after (C) treatment.

tact. Impedance levels $>400 \Omega$ indicate an extravascular or marginally intravascular position of the electrodes. A low impedance value alone, however, should not be used to confirm intravascular location of the RFS device because tumescence and edema can lead to falsely low extravascular numbers. After treatment, duplex ultrasound is used to confirm occlusion of the treated vein segment and patency of the deep veins (Figure 4C). Compression wraps are applied, and patients are instructed to ambulate for a minimum of 30 minutes daily and to refrain from prolonged sitting or standing for 3 to 5 days. Patients then undergo routine follow-up with duplex ultrasound evaluation at 72 hours to assess IPV ablation and deep system patency.

It is worth noting that an artery or a paired vein will commonly exist side by side with a perforator vein, and it is important when assessing results to avoid mistaking the patent artery or paired vein for the treated perforator vein.

DISCUSSION

There are several learning points from the early experience with RFA of IPV's, and the technique continues to evolve. Good ultrasound imaging is paramount to success, both in the initial detection of the IPV's and during their treatment. Attention to technical detail is very important, particularly in accurately accessing the vein. Intravascular treatment in a subfascial segment for adequate treatment time leads to the best closure rates, which currently average 70% to 80%. Visualizing the shaft and tip of the RFS to enable cannulation of the perforating vein in longitudinal view is a skill that requires development with practice. Patience and persistence are required because some IPV's will require repeat treatments.

Although SEPS has recently been the most common way to treat IPV's, there are several potential advantages of using ultrasound-guided endovenous RFA. The first is that the intervention is truly a minimally invasive procedure that can be performed in the office. Unlike SEPS, the approach is not limited by the perforating vein location. With RFA tech-

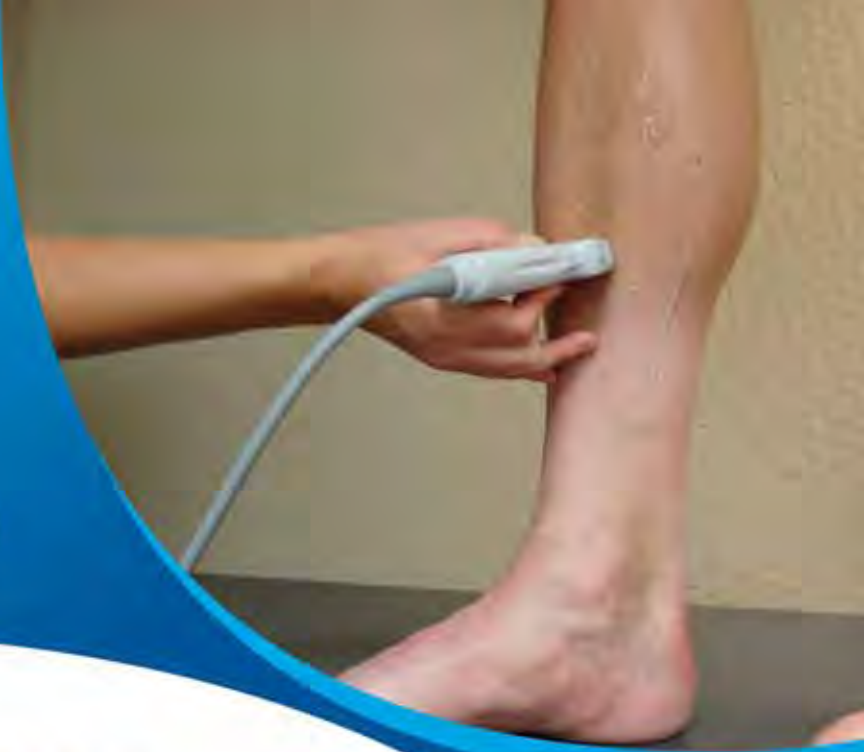nique, the physician can access IPV's at various positions including the more proximal Boyd's, Dodd's, the mid-thigh Hunter's, laterally located perforators, as well as perimalleolar located vessels, which are not easily accessed with SEPS. The procedure also allows the flexibility of repeat treatment for persistent or newly developed IPV's. In conclusion, RFA of IPV's is feasible, has promising early results, and will likely prove to be a very useful procedure for patients with CVI. ■

Eric K. Peden, MD, is from the Division of Vascular Surgery and Endovascular Therapy, Baylor College of Medicine, Houston, Texas. He has disclosed that he holds no financial interest in any product or manufacturer mentioned herein. Dr. Peden may be reached at (713) 798-8412; epeden@bcm.edu.

Alan B. Lumsden, MD, is from the Division of Vascular Surgery and Endovascular Therapy, Baylor College of Medicine, Houston, Texas. He has disclosed that he is a consultant to VNUS. Dr. Lumsden may be reached at (713) 798-8412; alumsden@bcm.edu.

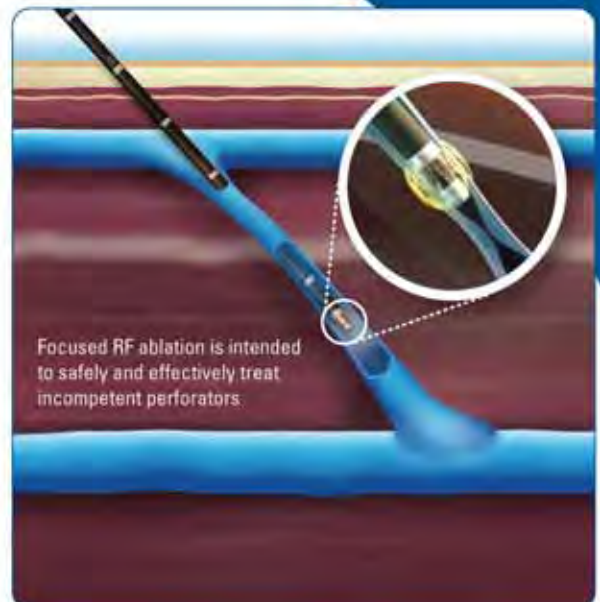
1. Linton R. The communicating veins of the lower leg and the operative technique for their ligation. *Ann Surg.* 1938;107:582-593.
2. Cockett F. The pathology and treatment of venous ulcers of the leg. *Br J Surg.* 1955;43:260-278.
3. Myers KA, Ziegenbein RW, Zeng GH, et al. Duplex ultrasonography scanning for chronic venous disease: patterns of venous reflux. *J Vasc Surg.* 1995;21:605-612.
4. Rutherford EE, Kianifard B, Cook SJ, et al. Incompetent perforating veins are associated with recurrent varicose veins. *Eur J Vasc Endovasc Surg.* 2001;21:458-460.
5. Gloviczki P, Bergan JJ, Rhodes JM, et al. Mid-term results of endoscopic perforator vein interruption for chronic venous insufficiency: lessons learned from the North American subfascial endoscopic perforator surgery registry. The North American Study Group. *J Vasc Surg.* 1999;29:489-502.
6. Pierik EG, van Urk H, Wittens CH. Efficacy of subfascial endoscopy in eradicating perforating veins of the lower leg and its relation with venous ulcer healing. *J Vasc Surg.* 1997;26:255-259.
7. Pierik EG, Toonder IM, van Urk H, et al. Validation of duplex ultrasonography in detecting competent and incompetent perforating veins in patients with venous ulceration of the lower leg. *J Vasc Surg.* 1997;26:49-52.
8. Bergan JJ, Murray J, Greason K. Subfascial endoscopic perforator vein surgery: a preliminary report. *Ann Vasc Surg.* 1996;10:211-219.
9. Gloviczki P, Cambria RA, Rhee RY, et al. Surgical technique and preliminary results of endoscopic subfascial division of perforating veins. *J Vasc Surg.* 1996;23:517-523.
10. Kalra M, Gloviczki P. Subfascial endoscopic perforator vein surgery: who benefits? *Semin Vasc Surg.* 2002;15:39-49.
11. Rutherford RB. *Vascular Surgery*, 5th edition. Philadelphia: WB. Saunders, 2000.
12. Sybrandy JE, van Gent WB, Pierik EG, et al. Endoscopic versus open subfascial division of incompetent perforating veins in the treatment of venous leg ulceration: long-term follow-up. *J Vasc Surg.* 2001;33:1028-1032.
13. van Rij AM, Hill G, Gray C, et al. A prospective study of the fate of venous leg perforators after varicose vein surgery. *J Vasc Surg.* 2005;42:1156-1162.
14. Whiteley MS HJ, Price BA, Scott MJ, et al. Radiofrequency ablation of refluxing great saphenous systems, Giacomini veins, and incompetent perforating veins using VNUS closure and TRLOP technique. *Phlebology.* 2003;18:52.

Not Scanning for Perforator Incompetence?



Here's why you should be...

- 1** *More than 50% of patients in a 293 patient study presenting with a refluxing GSV also had incompetent perforators¹*
- 2** *In the same study, 45% of incompetent perforators remained incompetent after treatment of the GSV¹*
- 3** *ClosureRFS™ is indicated for the treatment of incompetent perforators*



VNUS® ClosureRFS™ stylet treating perforator vein

VNUS ClosureRFS™ STYLET *The Radiofrequency (RF) Treatment for Perforators*



VNUS®
MEDICAL TECHNOLOGIES, INC.

VNUS Medical Technologies, Inc.
5799 Fontanos Way San Jose, CA 95138 USA
Tel: 408-360-7200 Fax: 408-365-8480
www.vnus.com

¹Blomgren, et al. Changes in superficial and perforating vein reflux after varicose vein surgery. *Journal of Vascular Surgery*, August 2005, pp 315 - 320.

VNUS, the VNUS logo and ClosureRFS are trademarks of VNUS Medical Technologies, Inc. Copyright © 2006 VNUS Medical Technologies, Inc. All Rights Reserved.

RF Obliteration of Saphenous Reflux

Long-term outcomes of endovenous RF obliteration of saphenous reflux for treating superficial venous insufficiency.

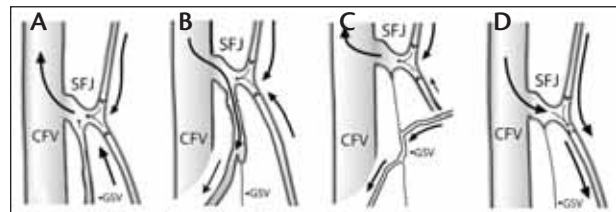
BY ROBERT F. MERCHANT, MD, FACS, AND OLIVIER PICHOT, MD, FOR THE CLOSURE STUDY GROUP*

Endovenous radiofrequency obliteration (RFO), also known as the Closure[®] procedure, was introduced in Europe in 1998 and in the US in 1999. The clinical benefits of this technique have been demonstrated through four separate randomized clinical studies comparing RFO with conventional vein stripping.¹⁻³ The short- and mid-term treatment outcomes have been reported by several groups.⁴⁻⁷ In this study, we report the 5-year follow-up results of a multicenter registry. Factors related to treatment failure and varicose vein recurrence were also analyzed.

MATERIALS AND METHODS

Data were collected in an ongoing multicenter, prospective registry. This report includes the results from all patients in the registry treated without concomitant high ligation. Patients were treated prior to October 2004 at 34 centers worldwide, with 12 centers contributing 5-year follow-up data. Patients with superficial venous insufficiency confirmed by duplex ultrasound scanning were considered as candidates for RFO treatment. Saphenous vein incompetence was diagnosed with saphenofemoral, saphenopopliteal, or truncal vein reflux >0.5 seconds in response to manual compression and release with the patient standing, or the Valsalva maneuver in 15° reverse Trendelenburg position. Exclusions for saphenous vein aneurysm and vein diameters greater than 12 mm were initially established as a conservative measure and were later discontinued after reports of routinely successful treatment in patients with these anatomical features, including vein diameter up to 24 mm.

A Closure catheter (VNUS[®] Medical Technologies, Inc., San Jose, CA) was advanced to the saphenofemoral junction (SFJ) or the saphenopopliteal junction (SPJ), and the electrodes were placed distal to the SFJ or SPJ under ultrasound guidance. Procedure evolution included gradual introduction of subcutaneous saline infiltration and later perivenous tumescent infiltration. Treatment temperature was set at 85°C. After starting RF energy delivery and achieving treatment temperature for 15 seconds, the catheter was with-



MERCHANT RF, DePalma RG, Kabinick LS. J Vasc Surg. 2002;35:1190-1196.

Figure 1. The three types of anatomical failure (left to right). Type I: Great saphenous vein (GSV) failure to occlude completely, with or without reflux present (A). Type II: partially recanalized GSV (B,C). Type III: the treated GSV is occluded, but reflux is present involving branches near the SFJ (D).

drawn at approximately 2 to 3 cm/min along the length of the vein while maintaining target temperature $\pm 3^{\circ}\text{C}$. Adjunctive procedures at the time of treatment included phlebectomy and sclerotherapy of visible varicose veins. Patients were advised to ambulate and return to normal activities shortly after the procedure.

After the procedure, a duplex ultrasound examination was routinely performed within 1 week (preferably within 72 hours) to check for any evidence of thrombus extension from the SFJ or SPJ into the deep system and to document the occlusion status of the treated veins. Further follow-up ultrasound scans and physical examinations were performed at 6 months, 1 year, and each year thereafter. Reflux was defined as any evidence of reverse flow >0.5 seconds in any treated vein segment or in the area of SFJ (or SPJ). As reported, RFO often started 1 cm to 2 cm below the SFJ, and the most common duplex finding after treatment was a short patent terminal GSV segment conducting prograde tributary flow through the SFJ.⁸ Vein occlusion was defined as absence of any bloodflow 3 cm inferior to the SFJ or SPJ along the length of treated vein segments. Symptom severity and clinical assessment according to CEAP (clinical, etiologic, anatomic, pathophysiologic) clinical classification were recorded at each visit.

TABLE 1. MAXIMUM PREOPERATIVE CEAP CLINICAL CLASS DISTRIBUTION

CEAP Clinical Class	% of Limbs
0	0.5%
1	2.5%
2	69.6%
3	10.1%
4	13.1%
5	1.2%
6	1.1%
Not recorded	1.9%

RESULTS

One thousand six patients (1,222 limbs) from 34 centers were treated. The average patient age was 47.4 ±12.1 years (range, 15-97 y), with a body mass index (BMI) of 24.8 ±4.9 (78.1% of the patients were female). The CEAP clinical class distribution before treatment is shown in Table 1. The most common symptoms were pain in 85.3% of limbs, fatigue in 78.6% of limbs, and edema in 39.2% of limbs.

All treated veins had reflux >0.5 seconds prior to treatment, documented by duplex ultrasound examination, as described previously. Among the veins treated, 89.1% were GSV limited to thigh segment (access at above the knee or just below the knee), 4.1% GSV from groin to ankle, 1.2% GSV limited to the below-the-knee segment, 4.3% small saphenous vein, and 1.3% accessory saphenous veins. The mean diameter, measured with the patient in the supine position, was 7.5 mm (range, 2-24 mm). Adjunctive phlebectomy was performed in 52% of limbs, and sclerotherapy was performed in 11% of limbs at the time of RFO treatment.

Vein Occlusion and Hemodynamic Outcomes

Limbs at risk and limbs available for follow-up at each time point are shown in Table 2. Immediate vein occlusion was achieved in 96.8% of limbs confirmed by duplex ultrasound examination within 1 week after the procedure. The vein occlusion rate at 5 years was 87.2%, and the absence of reflux rate was 83.8%. For those 30 limbs (3.2%) that did not achieve immediate occlusion, subsequent intervention to the GSV was done in three limbs, two with sclerotherapy and one with high ligation. As of the last reported follow-up, 24 limbs received no further GSV treatment. Seven of the 24 limbs had spontaneous occlusion at a later time point, and another three limbs had no further follow-up information.

Anatomical Failure Mode and Risk Factors

During a 5-year follow-up period on 1,222 treated limbs, duplex ultrasound examination identified 185 limbs that had either flow in the entire treated vein or a segment of it, or developed groin reflux despite a completely occluded GSV trunk. These findings were defined as anatomical failure. The mode of anatomical failure can be categorized into three types (Figure 1).

Type I (nonocclusion) failure referred to veins that failed to occlude initially and never occluded during follow-up; 23 limbs belonged to this category, consisting of 12.4% (23 of 185) of all anatomical failures. Among these 23 limbs, 34.8% (eight of 23) were significantly narrowed with no reflux, irrespective of a patent trunk.

Type II failure (recanalization) referred to veins that were initially occluded but recanalized, partly or completely, at a later time point. There were 129 limbs in this category, accounting for 69.7% (129 of 185) of the total anatomical failure. Among the type II limbs, 34.1% (44 of 129) exhibited no reflux. There was documentation in 23.3% (30 of 129) of type II limbs that the recanalization was directly related to either a refluxing tributary or an incompetent thigh perforator.

Type III failure (groin reflux) referred to situations in which the vein trunk was occluded but reflux was detected at the groin region, often involving an accessory vein. There were 33 type III limbs, making up 17.8% (33 of 185) of the total anatomical failure.

Only 19 (10.3%) of 185 limbs underwent reintervention to address the anatomical failure: 11 limbs with sclerotherapy resulting in secondary occlusion in nine limbs; two limbs re-treated successfully with RFO; one vein stripping; two high ligations; and three nonspecified.

Logistic regression analysis found two risk factors that were significant for anatomical failure: pullback speed ($P<.0001$) and BMI ($P<.0333$). The probability of anatomical failure increased by 1.28 times (95% CI: 1.13, 1.45) for each unit (1 cm/min) increase over 3 cm/min in pullback speed using a treatment temperature of 85°C; the probability of anatomical failure increased by 1.04 times (95% CI: 1.00, 1.07) for each unit (1 kg/m²) increase over 25 kg/m² in BMI. When further identifying which risk factor was associated with which type of anatomical failure, it was found that the pullback speed was a risk factor for only type I and type II failure, but not type III failure. The BMI, however, failed to show significance for any individual failure type, likely due to small sample size resulting in insufficient statistical power in each failure category.

It is important to point out that anatomical failure does not necessarily result in clinical failure. As detailed

TABLE 2. VEIN OCCLUSION AND HEMODYNAMIC OUTCOMES

	1 wk	6 mo	1 y	2 y	3 y	4 y	5 y
Limbs at risk	1,222	1,220	1,206	1,141	991	833	406
Limbs available for follow-up	985	518	473	263	133	119	117
Vein occlusion	96.8%	89.2%	87.1%	88.2%	83.5%	84.9%	87.2%
Absence of reflux	96.6%	91.3%	88.2%	88.2%	88%	86.6%	83.8%

in the following information, the majority of patients experienced symptom relief after the procedure and remained asymptomatic, despite anatomical failure.

Clinical Symptoms and Signs

Significant symptom improvement was seen even in patients with anatomical failures. In those patients, 70% to 80% of limbs remained asymptomatic up to 5 years after treatment, suggesting the clinical benefit of the procedure even in patients with a treated limb judged as anatomical failure. When comparing the percentage of asymptomatic patients at each follow-up time point, no statistical significance was found among the type I, II, or III patients (χ^2 test). The data from these anatomical failure patients were combined and compared with anatomically successful patients. As expected, the percentage of asymptomatic limbs was slightly lower in the anatomical failure group compared with the anatomical success group.

The cumulative varicose vein recurrence rate at 5 years was 27.4% (32 of 117). When examining the impact of anatomical failure on varicose vein recurrence, it was found that type II ($P < .0001$) and type III ($P = .0009$) failures were risk factors for recurrence. The odds ratio for varicose vein recurrence was 3.8 (95% CI: 2.5, 5.9) when there was a type II failure and 4.0 (95% CI: 1.8, 9.2) when there was a type III failure.

Complications

Early complications in this series included 0.9% deep venous thrombosis or clot extension into the common femoral vein, 1.2% skin burn, 2.9% clinical phlebitis, and 0.2% infection at the vein access site. Skin burn complications occurred primarily before the implementation of tumescent infiltration. No limbs exhibited lymphedema at any follow-up visits. One of the patients with deep vein thrombosis developed pulmonary embolism, as reported elsewhere.^{7,9}

Paresthesia, often presenting as focal hypoesthesia, was observed in 121 of 985 limbs (12.3%) at initial 1-week follow-up. The incidence decreased to 7.3% by 6 months and was 2.6% at 5 years. For GSV below-the-knee treatment, the paresthesia rate was 13.3%, 11.6%, 7.7% at 1 week, 6 months, and 5 years, respectively, suggesting a trend toward higher paresthesia rate with below-the-knee GSV treatment. The paresthesia rate associated with small saphenous vein treat-

ment was 8.9% and 9.5% at 1 week and 6 months, respectively.

CONCLUSION

Five-year follow-up on patients treated with endovenous RFO has demonstrated that vein occlusion and clinical improvement are durable. Risk analysis in this international multicenter registry identified catheter pullback speed and BMI as the two risk factors associated with RFO anatomical failures. Although historical data on traditional vein stripping can only serve as a reference and not direct comparison, the clinical recurrence and neovascularization appear to be low in RFO patients. The data from this report and from randomized trials of RFO versus vein stripping indicate that RFO provides long-term efficacy and may be better for the patients.¹⁻³ ■

**Presented at the 17th annual meeting of the American Venous Forum, February 9-13, 2005, San Diego, California.*

Robert F. Merchant, MD, FACS, is from the The Reno Vein Clinic, Reno, Nevada. He has disclosed that he is a paid consultant and an owner/offshareholder in VNUS. Dr. Merchant may be reached at (775) 329-3100; doc@renoveinclinic.

Olivier Pichot, MD, is from the Vascular Medicine Division, CHU de Grenoble, Grenoble, France. He has disclosed that he is a paid consultant in VNUS. Dr. Pichot may be reached at opichot@wanadoo.fr.

1. Rautio T, Ohinmaa A, Perala J, et al. Endovenous obliteration versus conventional stripping operation in the treatment of primary varicose veins: a randomized controlled trial with comparison of the costs. *J Vasc Surg.* 2002;35:958-965.
2. Lurie F, Creton D, Eklof B, et al. Prospective randomized study of endovenous radiofrequency obliteration (Closure procedure) versus ligation and stripping in a selected patient population (EVOLVeS Study). *J Vasc Surg.* 2003;38:207-214.
3. Stötter L, Schaaf I, Fendl R, et al. Radiowellenobliteration, invaginierstes Stripping oder Kryostripping: Welches Verfahren belastet den Patienten am wenigsten? Eine prospektive, randomisierte Vergleichsstudie. *Phlebologie.* 2005;34:19-24.
4. Weiss RA. Endovenous techniques for elimination of saphenous reflux: a valuable treatment modality. *Dermatol Surg.* 2001;27:902-905.
5. Weiss RA, Weiss MA. Controlled radiofrequency endovenous occlusion using a unique radiofrequency catheter under duplex guidance to eliminate saphenous varicose vein reflux: A 2-year follow-up. *Dermatol Surg.* 2002;28:38-42.
6. Kistner RL. Endovascular obliteration of the greater saphenous vein: The closure procedure. *Jpn J Phlebol.* 2002;13:325-333.
7. Merchant RF, DePalma RG, Kabnick LS. Endovascular obliteration of saphenous reflux: A multicenter study. *J Vasc Surg.* 2002;35:1190-1196.
8. Pichot O, Kabnick LS, Creton D, et al. Duplex ultrasound findings two years after great saphenous vein radiofrequency endovenous obliteration. *J Vasc Surg.* 2003;39:189-195.
9. Manfrini S, Gasbarro V, Danielsson G, et al. Endovenous management of saphenous vein reflux. Endovenous Reflux Management Study Group. *J Vasc Surg.* 2000;32:330-342.

Endoluminal Treatment of Lower-Limb Varicose Veins by Radiofrequency and Endovenous Laser

An overview comparing endoluminal and classic open treatment.

BY MICHEL PERRIN, MD

New endoluminal treatments, namely radiofrequency (RF) and endovenous laser (EVL) obliteration, are currently challenging the traditional methods of open surgery that have been used for decades in treating primary varicose veins. More than 120 articles on RF and EVL have been published in the English literature, which provide information that allows a comparison of the two techniques.

METHODS

Both RF and EVL heat the vein wall inside the venous lumen to achieve obliteration, but their modes of action and devices are different. Whereas RF uses only one type of device manufactured and distributed by a sole company, EVL uses different types of lasers, manufactured and marketed by more than 10 companies. Therefore, RF benefits from a well-defined procedural protocol, in contrast to EVL, which presents multiple variants.

RESULTS

In an *ex vivo* developed model, the effects of RF and EVL (980 nm) were compared,¹ with the conclusion that histologic evaluation after RF demonstrated homogeneous circular thermal alteration with disintegration of intima and media structures (Figure 1). Conversely, histologic evaluation after EVL showed large variations of thermal tissue effects from major tissue ablation and vessel wall disruption

to minor effects, indicating that EVL treatment carries probable risks of vessel perforation or undertreatment that can lead to recanalization (Figure 2).

The short-term, 1-, 2-, and 3-year postoperative clinical status was studied in four controlled²⁻⁷ randomized trials (RCTs) comparing RF with open surgery, including three studies²⁻⁶ that used a quality-of-life questionnaire and another study concerning repeat surgery. The results, including postoperative pain, return to normal activity, and duration of convalescence, were more favorable after RF versus open surgery. A randomized trial study comparing EVL to open surgery is available.⁸ There was no difference on the postoperative pain profile between EVL and open surgery. Large bruising was 20% in the EVL group and 60% in the stripping group. Edema was more intense, and sick leave was longer in

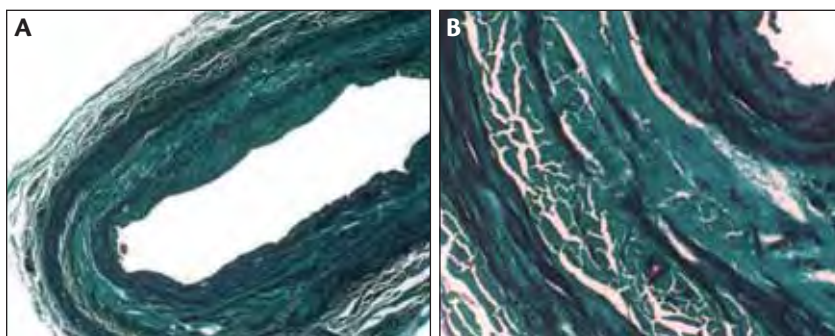


Figure 1. Great saphenous vein histopathology after Closure® (VNUS Medical Technologies, Inc., San Jose, CA) (A). Trichrome light-green-coloration demonstrating homogeneous circular thermal alteration with disintegration of intima and media structures (B). (Reprinted with permission from Perrin M. Traitement endovasculaire des varices des membres inférieurs. In: Techniques chirurgicales-Chirurgie Vasculaire. Elsevier Masson SAS; 2003:12).

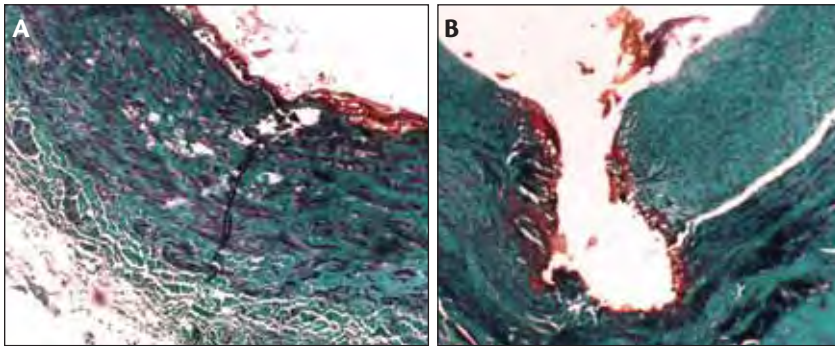


Figure 2. Great saphenous vein histopathology after endovenous laser (A). Trichrome light-green coloration showing large variations of thermal tissue effects from major tissue ablation and vessel wall disruption to minor effects (B). (Reprinted with permission from Perrin M. *Traitement endovasculaire des varices des membres inférieurs*. In: *Techniques chirurgicales-Chirurgie Vasculaire*. Elsevier Masson SAS; 2003:12.)

technique is that the duration of the procedure is shorter than that for RF due to the faster pulling of the catheter. The new VNUS ClosureFAST catheter (VNUS Medical Technologies, Inc.) might minimize this difference.

A cost comparison of the two techniques indicates that the EVL fiber is cheaper than the RF catheter, with the opposite being true for the respective generators. The global cost of the RF procedure (including convalescence) was compared to classical surgery in one study. The findings favor RF for active patients.⁵

the stripping group.

In another nonrandomized, prospective, short-term study, EVL appears to be more favorable than open surgery.⁹ Another randomized controlled trial comparing RF to EVL demonstrated better primary obliteration and less postoperative pain and bruising with RF.¹⁰

In terms of thromboembolic complications investigated by systematic duplex ultrasound examination, RF and EVL presented an approximately equal rate of 0.5%. Other postoperative complications were transient. RF has been associated with transient sensory nerve complications, such as paresthesia, whereas pain was more pronounced after EVL.

There is no outcome randomized controlled trial comparing RF to EVL or sclerotherapy versus endoluminal thermal obliteration. In terms of signs and symptoms, detailed results were available at 5-year follow-up for RF.¹¹ Improvement was very significant compared to the preoperative status and was roughly equivalent to that previously reported for classical surgery. Clinical results after EVL are less well-documented and the longest follow-up is at 2 years.

Hemodynamic results by duplex ultrasound examination are well-documented for RF and EVL. Vein obliteration after EVL was reported by various groups to be between 76% to 96.8% at 1- to 2-year follow-up; vein obliteration was 87.2% after RF in a multicenter study (117 limbs), and varicose vein recurrence was 27.4% at 5-year follow-up.

Correlation between clinical and hemodynamic results was established for RF at 3-year follow-up and showed a strong link between the clinical results and the absence of reflux.

One of the advantages usually credited to the EVL

DISCUSSION

Several points are worth highlighting. First, the absence of the neovascularization phenomenon, in particular at the saphenofemoral junction after endoluminal surgery, is well-documented for RF ablation (Figure 3). It is known that this phenomenon, which occurs frequently (ranging from 20% to 40% at 5 years after open surgery), plays an important role in the incidence of

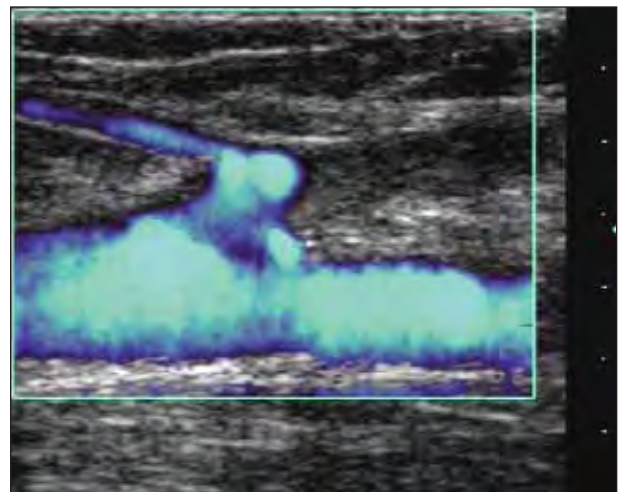


Figure 3. Postoperative duplex scanning after the endovenous RF procedure (Closure). The termination of the great saphenous vein is occluded. There is a persistent short patent stump at the saphenofemoral junction (SFJ), with a patent superficial epigastric tributary vein with prograde flow through the SFJ. No neovascularization phenomenon is present. (Reprinted with permission from Perrin M. *Traitement endovasculaire des varices des membres inférieurs*. In: *Techniques chirurgicales-Chirurgie Vasculaire*. Elsevier Masson SAS; 2003:12.)

recurrence.¹² Second, the incidence of postoperative deep vein thrombosis assessed with systematic postoperative duplex ultrasound appears to be approximately 0.5%. It is notable that the incidence of postoperative deep vein thrombosis after high ligation stripping was recently reported to be 5.3 %.¹³

CONCLUSIONS

In the absence of long-term (beyond 5 years) controlled study outcomes comparing classical surgery to endoluminal surgery, the endoluminal approach has demonstrated to be less aggressive postoperatively, with satisfactory efficacy at mid-term.

Suppression of the saphenous vein reflux exhibits an enduring treatment efficacy (clinically, anatomically, and hemodynamically) for up to 5 years for RF and 2 years for EVL. ■

Michel Perrin, MD, is from Vascular Surgery, Clinique du Grand Large, Chassieu, France. He has disclosed that he is a paid consultant to VNUS. Dr. Perrin may be reached at +33 4 72 057 266; m.perrin.chir.vasc@wanadoo.fr.

- Schmedt C-G, Skroka R, Meissner OA, et al. Investigation on radiofrequency and laser (980 nm): effects after endoluminal treatment of saphenous vein insufficiency in an ex-vivo model. *Eur J Vasc Endovasc Surg.* 2006;32:318-325.
- Lurie F, Creton D, Eklof B, et al. Prospective randomized study of endovenous radiofrequency obliteration (closure procedure) versus ligation and stripping in a selected patient population (EVOLVES Study). *J Vasc Surg.* 2003;38:207-214.
- Lurie F, Creton D, Eklof B, et al. Prospective randomized study of endovenous radiofrequency obliteration (closure) versus ligation and vein stripping (EVOLVEs): two-year follow-up. *Eur J Vasc Endovasc Surg.* 2005;29:67-73.
- Perala J, Rautio T, Biancari F, et al. Radiofrequency endovenous obliteration versus stripping of the long saphenous vein in the management of primary varicose veins: 3-year outcome of a randomized study. *Ann Vasc Surg.* 2005;19:1-4.
- Rautio T, Ohinmaa A, Perala J, et al. Endovenous obliteration versus conventional stripping operating in the treatment of primary varicose veins: a randomized controlled trial with comparison of the costs. *J Vasc Surg.* 2002;35:958-965.
- Stötter L, Schaaf I, Bockelbrink A. Comparative outcomes of radiofrequency endoluminal ablation, invagination stripping and cryostripping in the treatment of great saphenous vein. *Phlebology.* 2006;21:60-64.
- Hinchliffe RJ, Uhbi J, Beech A, et al. A prospective randomised controlled trial of VNUS closure versus surgery for the treatment of recurrent long saphenous varicose veins. *Eur J Vasc Endovasc Surg.* 2006;31:212-218.
- de Medeiros CA, Luccas GC. Comparison of endovenous treatment with an 810 nm laser versus conventional stripping of the great saphenous vein in patients with primary varicose veins. *Dermatol Surg.* 2005;31:1685-1694.
- Vuylsteke M, Van den Bussche D, Audenaert EA, et al. Endovenous laser obliteration for the treatment of primary varicose veins. *Phlebology.* 2006;21:80-87.
- Morrison N. Saphenous ablation: what are the choices, laser or RF energy. *Semin Vasc Surg.* 2005;18:15-18.
- Merchant RF, Pichot O, for the Closure Study Group. Long-term outcomes of endovenous radiofrequency obliteration of saphenous reflux as a treatment for superficial venous insufficiency. *J Vasc Surg.* 2005;42:502-509.
- Fischer R, Chandler JG, De Maeseneer MG, et al. The unresolved problem of recurrent saphenofemoral reflux. *J Am Coll Surg.* 2002;195:80-94.
- Van Rij AM, Chai G, Hill GB, et al. Incidence of deep vein thrombosis after varicose vein surgery. *Br J Surg.* 2004;91:1582-1585.

www.vnus.com

The V&V Advantage

VNUS® Medical Technologies and VENOSAN® together to provide the best options in Medical Compression Stockings



- *Better Fit – Better Comfort – Easier Sizing*
- *VENOSAN offers the most complete line of compression stockings for men and women*
- *V&V Boutique programs provide a new level of personal service to your patients as well as revenue for your practice*

TO ORDER, CALL 1-888-797-VEIN(8346)



www.venosanusa.com

VNUS® is the registered trademark of VNUS Medical Technologies, Inc.
VENOSAN® is the registered trademark of SALZMANN, AG, St. Gallen, Switzerland.
Copyright © 2006 VNUS Medical Technologies, Inc. All Rights Reserved.



Building a Vein Practice

An overview of the important elements for creating your vein practice.

BY PAUL McNEILL, MD

Physicians are entering vein care to create positive change in their professional lives. New solutions that solve varicose vein problems without the discomfort, scarring, or prolonged recovery of traditional vein stripping have patients and referring doctors searching for a vein care specialist. This article outlines the elements of building a vein care practice.

Modern vein care requires knowledge of venous anatomy, endovenous techniques, microphlebectomy, sclerotherapy, and compression therapy. Valuable instruction on the clinical and business aspects of a vein practice is available through multiple continuing medical education venues, texts, and on-site training opportunities. Meetings by the American College of Phlebology, the American Venous Forum, and the International Vein Congress, as well as the Total Vein Care course sponsored by VNUS Medical Technologies, Inc. (San Jose, CA) provide valuable instruction on the clinical and business aspects of a vein practice.

VASCULAR TESTING

Venous duplex evaluation is central to the diagnosis and treatment of venous disease. Performance of venous testing in your office is optimal for practice growth. Most busy vein practices eventually operate a vascular lab as a patient convenience and an important source of revenue. If you are not currently operating a vascular lab in your practice, refer patients to an outside lab and provide guidance to technologists regarding complete venous testing, including assessment for reflux throughout the superficial venous system. Orient reading physicians to the interpretation of duplex findings before and after endovenous treatment. Venous duplex is required to perform office-based vein procedures.

BUILD IT AND THEY WILL COME

Patients with varicose and spider veins do not perceive themselves as being ill. They seek a good clinical and cosmetic outcome from their leg vein treatment. Often, they research your reputation and experience before making an appointment and judge you by the appearance of your office and the performance of your staff. Long wait times for appointments and drab or

highly clinical surroundings are not appealing to these vein patients. A beautiful, friendly office creates a buzz in the community, puts patients at ease, and encourages referrals. When starting out, consider scheduling vein care appointments and procedures in a designated bracket of time, such as one or two afternoons each week so that the activity level in the office is low, allowing patients to experience you and your office in a relaxed mode of operation. This allows you and your staff to put your best foot forward. Make sure the staff is prepared to answer phones, greet patients, and respond to questions regarding your services. Request that your office staff ask each new patient how he or she heard about your practice. Keep a list of referring physicians to track their referring activity.

Engineer the workflow with your initial vein patients to optimize care, resources, staffing, and scheduling. Patient evaluation forms and educational materials that you author standardize the clinical approach and inform patients. Knowledgeable patients will market your services to others. Obtaining insurance authorization requires complete documentation, including symptoms, physical findings, and duration of compression therapy. Photo documentation is sometimes required.

MARKETING

You may not have previously used marketing in your medical practice, but it is essential to practice growth in vein care. Market to physicians by educating them about the natural history of venous disease, the effectiveness of treatment, and the ease of recovery. Patients must be invited to consider vein treatment for these reasons, as well as the cosmetic benefits.

Develop Your Identity

Consider the following points in marketing your own practice growth success strategy.

- Name your practice. Select a name that clearly and concisely indicates what type of services you offer.
- Develop a logo. A logo provides a unifying element that links marketing materials and creates a consistent image. Professional assistance in logo design is available but do not discount your own ability in creating a logo.

• Create a practice Web site. A Web site that contains information about your services, credentials, staff, and facilities is essential. Patients consult the Web before selecting where they will seek care. Search engine optimization can get your practice and potential patients connected quickly.

• Physician referral sources. A referral network must be cultivated by educating physicians about venous disease as a medical problem, not just a cosmetic issue. Emphasize early intervention through patient referral to avoid the late complications of venous disease. Arrange "lunch and learns" to teach vein care to referring doctors and to establish a personal bond as a basis for referring patients to your practice. Presentations at hospital grand rounds and other physician assemblies, as well as hosting informative dinners are good opportunities to establish yourself as an expert.

• Market directly to patients. Communicate with new potential patients through direct mail, educational materials, practice brochures, print advertising, community service ads, hospital announcements, newspaper articles, interviews, and radio and television ads. Inform and educate your existing patients by displaying posters, playing educational videos, and placing brochures in your waiting room. It is recommended that your ads mention a free vein consultation or free vein screening to give the reader a reason to make an appointment. Radio and television ads, as well as vein screening events can attract new patients. The Practice Marketing Department at VNUS Medical Technologies, Inc. will help you plan and execute your marketing strategy. Getting your practice name and identity in front of the community regularly is important. Remember, marketing is nothing more than effective patient education and strategic promotion of your services.

• Public relations. Get the attention of local media reporters (ie, TV stations and newspapers). Have a successful patient story with before and after photos that reporters could use as the basis for an article or news clip on your practice. Public relations initiatives can reach many patients in your community.

• Common sense. Referring physicians and patients are your customers. Treat every patient like a family member and give them the same kind of service you want from a specialist. A steady stream of new vein patients will develop if you implement and follow through with the right strategies and initiatives. ■

Paul McNeill, MD, is a vascular surgeon with Capitol Vein & Laser Center in Frederick, Maryland. He has disclosed that he is a paid consultant to and receives grant and research funding from VNUS. Dr. McNeill may be reached at (301) 695-8346; pmcneill@fmh.org.

Practice Development Programs and Tools from VNUS Medical Technologies, Inc.

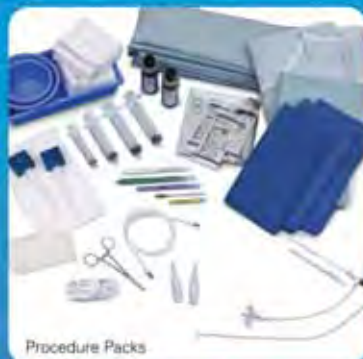VNUS Medical Technologies is a leader in partnering with physicians to build their vein practices. Some of the programs and tools VNUS can provide include:

- Practice Development Kit with educational, marketing, and reimbursement materials for you and your staff.
- Patient brochures, posters, and educational video.
- Web site content, animations, and images on the VNUS Closure procedure to update your Web site.
- Images for brochure creation.
- Direct mail programs with postcard and letter templates, advertising templates, newsletter article templates, and radio ad scripts.
- "Screenings for Success" program for planning and running patient screening events, complete with a comprehensive manual, materials, and templates.
- Presentation materials for potential patients.
- Press Release kit that can be customized for your practice, including video footage and animation you can use of the VNUS Closure procedure.
- Patient tracking tool.
- Direct mail programs targeted to referring physicians.
- Kit to assist in "lunch and learn" sessions for referring physicians, including leave-behind materials.
- PowerPoint slides developed for presentations to referring physicians.
- Interactive "Healthy Legs" CD-ROM to educate your referring physicians on venous disease.

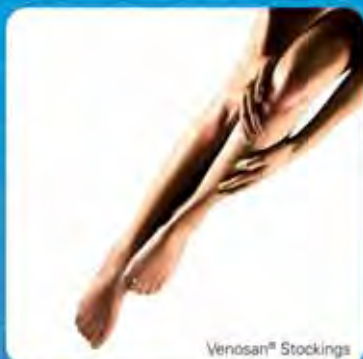Your One-Stop Endovenous Source



VarEx™ Phlebectomy Instruments



Procedure Packs



Venosan® Stockings



Compression Bandages



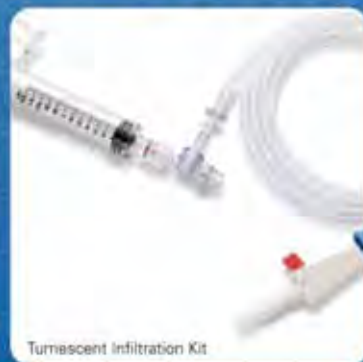Veinlite® I



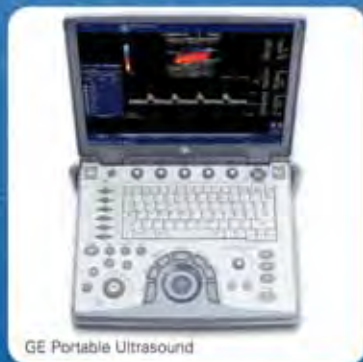Micro Puncture Kit



VarEx™ Phlebectomy Instruments



Turbocent Infiltration Kit



GE Portable Ultrasound

**Accessories, packs and instruments
for your endovenous procedures.**

TO ORDER, CALL 1-888-797-VEIN(8346)



VNUS[®]
MEDICAL TECHNOLOGIES, INC.

VNUS Medical Technologies, Inc.
5799 Fontanoso Way San Jose, CA 95138 USA
Tel: 408-360-7200 Fax: 408-365-8480
www.vnus.com

Copyright © 2006 VNUS Medical Technologies, Inc. All Rights Reserved.

NEW IN
2007

“A New Revolution in the Treatment of Varicose Veins”

- Alan Lumsden, MD
Houston, TX

“As fast as laser, with the rapid and mild patient recovery you expect from RF.”

- Jose Almeida, MD
Miami, FL

“Simplified energy delivery combining the advantages of RF with the speed of laser.”

- Thomas Proebstle, MD
Heidelberg, Germany

NEW, FASTER, EASIER

VNUS[®] ClosureFAST[™] Radiofrequency Catheter

- New ‘segmental ablation’ approach treats 7 cm vein segment in 20 seconds
- 45 cm vein length typically treated in 3 to 5 minutes
- Temperature-controlled energy delivery
- Uniform treatment with no pullback speed variation
- Works with existing VNUS RFGPlus[™] generators after field software upgrade



VNUS[®]
MEDICAL TECHNOLOGIES, INC.

VNUS Medical Technologies, Inc.
5799 Fontanoso Way San Jose, CA 95138 USA
Tel: 408-360-7200 Fax: 408-365-8480
www.vnus.com

Copyright © 2006 VNUS Medical Technologies, Inc. All Rights Reserved.